

EFSUMB – European Course Book

Editor: Christoph F. Dietrich

Ultrasound of the adrenal glands

Dieter Nürnberg (corresponding author), Agnes Szebeni², František Zát'ura³

²Budapest, Hungary. ³Olomouc, Czech Republic

Corresponding author:

Prof. Dr. Dieter Nürnberg

Ruppiner Kliniken GmbH

Department of Internal Medicine / Gastroenterology and Oncology

Fehrbelliner Str. 38

16816 Neuruppin

d.nuernberg@ruppiner-kliniken.de

Content

Topographic Remarks	2
Anatomy	4
Echogenicity.....	4
Examination technique.....	5
Normal adrenal gland.....	5
Enlarged adrenal gland.....	6
Differential diagnosis (differentiation from other structures in the surrounding area)	6
Adrenal gland hyperplasia.....	7
Adrenal Cyst.....	7
Intra-adrenal Hemorrhage (Hematoma)	8
Adrenal Abscess.....	9
Cystic Tumour.....	9
Differentiation of benign and malignant lesions	9
Benign adrenal gland tumours.....	9
Adenoma	9
Lipoma, Myelolipoma.....	10
Calcification	11
Malignant adrenal gland tumours.....	12
Metastases	12
Pheochromocytoma.....	13
Lymphoma	14
Adrenal Carcinoma	15
Rare entities.....	16
Neuroblastoma	16
Other tumours.....	16
Incidentaloma	16
Ultrasound-guided Fine-needle Aspiration of an Adrenal Lesion	19
Special ultrasound techniques in differentiation of adrenal gland tumours	20
Colour Doppler imaging.....	20
CEUS (Contrast enhanced ultrasound)	21

Topographic Remarks

The right kidney and the inferior vena cava are landmarks for the examination of adrenal glands on the right side. On the left side the aorta, the lower pole of the spleen and the upper pole of the kidney are points of orientation. The most favorable planes for ultrasound scanning of the right adrenal gland are a [right transcostal scan](#) or an subcostal flank scan or oblique subcostal scan. On the left side it is better to use an intercostal flank scan through the spleen.

The adrenal glands are located within the retroperitoneum. The right adrenal gland [faces](#) supramedial the right kidney and posterolateral to the inferior vena cava. These are the principal landmarks on the right side. Typically the right adrenal gland is visualized behind the right lobe of the liver and anterior to the inferior (lumbar) crus of the diaphragm.

The left adrenal gland is inherently more difficult to scan than the right because it lacks the acoustic window of the liver and is obscured by air in the stomach. It is imaged with an intercostal flank scan directed through the spleen. The key landmarks are the aorta medially, the left inferior crus of the diaphragm (Crus diaphragmaticum sinister and the lower pole of the spleen or upper renal pole laterally. Not infrequently, the adrenal glands extend down to the level of the renal hilum [(1;2)]. Besides the kidneys, they are bordered by the liver and inferior vena cava on the right side and by the aorta and tail of the pancreas on the left side. Enlarged adrenal glands (**wings of glands > 2 – 5 cm long and 6 – 10 mm thick**) are detectable in a high percentage of cases, the normal sized adrenal glands are visible with trained examination techniques and by using high resolution technology (right > left). The adrenal region on each side appears as a triangular echogenic area bordered by the landmarks noted above [Figure 1 and 2].

Figure 1 Diagram of the adrenal glands showing their relations to neighboring organs.

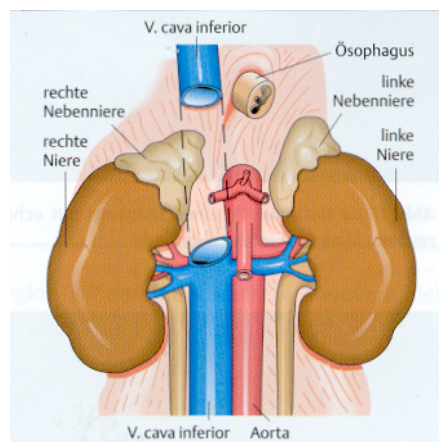
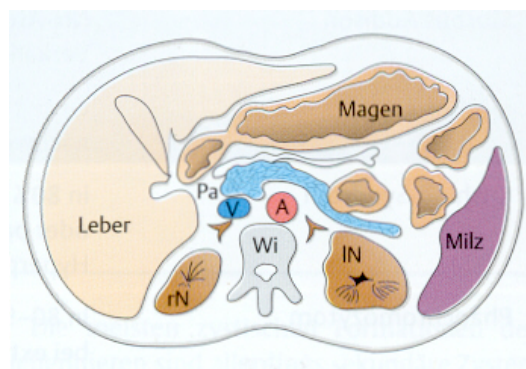


Figure 2 Cross-sectional diagram at the level of the adrenal glands. The adrenal glands are the Y-shaped structures lying anteromedial to the kidneys. Pa = pancreas; rK = right kidney; lK = left kidney; A = aorta; V = inferior vena cava; SC = spinal column.



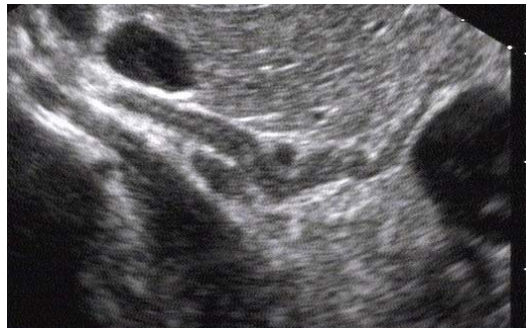Anatomy

The adrenal glands are small, caplike glandular organs situated in close proximity to the kidneys. Often these “suprarenal” glands are incorrectly looked for above the kidneys, but the term “adrenal” correctly implies that each gland is predominantly medial to the upper pole of the associated kidney. The right adrenal gland has a linear or V shape, while the left adrenal gland is more V- or Y-shaped. The wings of each gland are 2 – 5 cm long and 6 – 10 mm thick [(2;3)]. Their physiological function is hormone production. The adrenal cortex secretes cortisol, aldosterone, and sex hormones, while the adrenal medulla secretes epinephrine and norepinephrine.

The normal adrenal glands are difficult to visualize with ultrasound. This requires good scanning conditions, a high-resolution transducer, and a meticulous examination by a knowledgeable sonographer. It is more accurate, then, to speak of evaluating the “adrenal region” rather than the glands themselves. CT can consistently define the normal-sized adrenal glands, giving this study a priority role in the primary imaging of these structures.

The EUS of the upper gastrointestinal tract shows the adrenal gland in the best picture quality [Figure 3], but this is possible only on the left side, the right adrenal gland in EUS is detectable only in 30-40 % of examinations [(4) (5)]. The attending vessels (left Aa. and Vv. suprarenales) are visible only with the endosonographical technique. In primary diagnostics the indicated EUS is not **favored**. [(1;6-9)]

Figure 3 Sonoanatomy of the left adrenal gland - image by high resolution endosonography. The proximal and the caudal limbs are visible in high resolution quality and the adrenal gland-marrow is more echogenic.

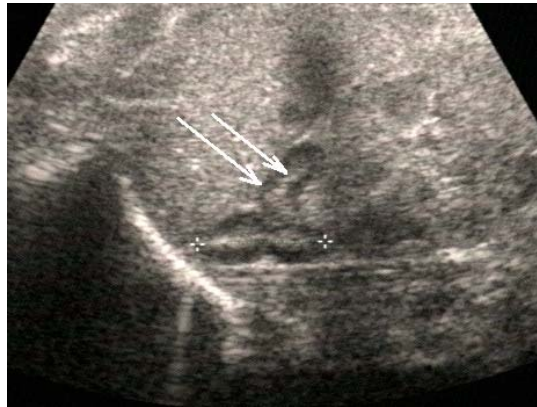


Echogenicity

When the normal adrenal glands are seen using ultrasound, they have a long and hyperechoic, narrow shape, typically with 5 layers of stratification with a hypoechoic cortex and medulla.

The adrenal glands can almost always be visualized in newborns [(10-12)]. The physiological hypertrophy at this stage of life results in relatively large glands that can easily be identified using ultrasound and show clear corticomedullary differentiation **Erledigt !** [Figure 4].

Figure 4 Normal adrenal gland of an infant, consisting of a hyperechoic medulla and hypoechoic cortex.



Examination technique

The normal position for examination is the dorsal decubitus position. On the right side of the body one would optimally use a subcostal flank scan or oblique subcostal scan. On the left side it is better to use an intercostal flank scan through the spleen. Often better scanning is possible in a lateral decubitus position (on the left side looking through the liver or (in right lying position scanning through the spleen), or in prone position. Rarely it is useful to examine (the patient) in a lying position over a roll (so-called gabled position) [(13)] especially in the prone position. In case of intercostal scanning, slow and deep breathing of the patient move those part of the organ from its place, lying originally under the ribs. Thus, the visible region increasing. The guide-lines or landmarks have already been explained. Normally used transducer is a convex probe with high resolution in depth and in tissue-harmonic-functions.

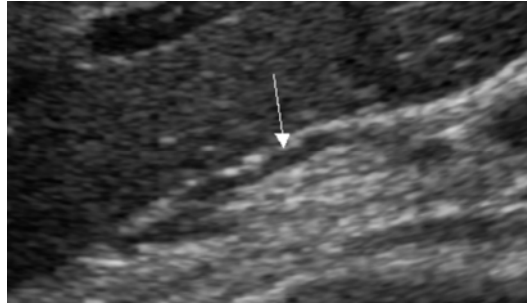
Acoustic obstacles of adrenal gland examination are usually air in the intestine which can be reduced when we prepare the patient. However, the adrenal gland has a good position so it is usually accessible even at the patient who is not well prepared.

The basic need for the examination is examination by convex abdominal transducer (3-6 MHz in B mode). A Tissue Harmonic Imaging can help for better tissue differentiation. Vascularisation can be evaluated by Power Doppler, microvascularisation can be examined also by CEUS. There are also interventional methods that can improve the differentiation. Those methods enable the transducer to get close to the targetted tissue. EUS –Endoscopic ultrasonography can be used especially for imaging of left adrenal gland. [(14;15)]

Normal adrenal gland

On the right side the normal adrenal gland regularly is visible using optimized examining techniques (approximately 1 x 4 cm) [Figure 5]. The left adrenal gland is in generally only visible in about 40-50 % of all cases. [(7)]

Figure 5 The normal adrenal gland on right side is visible dorsal of right liver lobe as a narrow layered organ with two shanks.



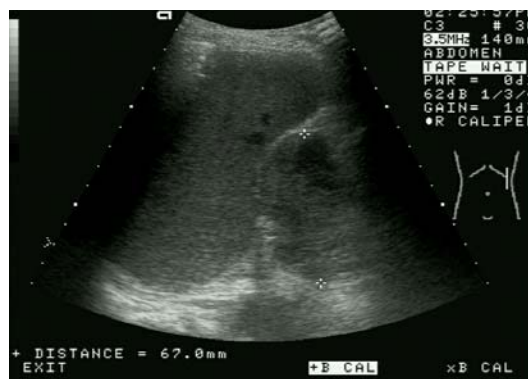Enlarged adrenal gland

In adults, however, the adrenal glands are usually only visible when they are enlarged. Some types of enlargement have pathological significance. Diseases of the adrenal glands may or may not be associated with endocrine symptoms [Table 3]. Examination of the adrenal region is indicated for the staging of oncological diseases (M-staging) and in endocrinological investigations. Adrenal abnormalities are, however, often detected coincidentally. In the absence of an underlying disease, an incidentally detected solid adrenal mass is called an incidentaloma [Figure 10].

Differential diagnosis (differentiation from other structures in the surrounding area)

Enlarged or tumorous adrenal gland require distinguishment from other possibly tumorous structures in the surrounding area of the adrenal gland. In differentiating one has to consider tumours of the kidney, pancreas [Figure 6] and spleen (especially accessory spleen) or vascular abnormalities and lymphoma. In the differential diagnosis it must taken into account, that adrenal gland tumours always dislocate the surrounding structures. When the adrenal gland tumour is extremely large, it may be difficult to find the neighbouring organs.

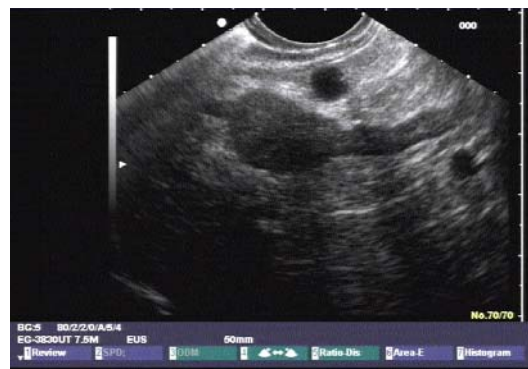Figure 6 Transsplenic scan of a large, hypovascular malignant tumour of the pancreas tail



Adrenal gland hyperplasia

Hyperplastic adrenal glands are usually hypoechoic, especially in the cortical zone. They appear plump and elongated, may show low-level nodular echoes and the borderline between cortex and marrow disappears. The adrenal gland here are larger than 10 mm, usually are only moderately enlarged (to 2 cm) [Figure 7]. Adrenal hyperplasia can occur, for example, as an adaptive response in ACTH-dependent Cushing syndrome. It may have a paraneoplastic cause, or it may occur in hyperaldosteronism. The hyperplasia is even bilateral in most cases. For the advanced examiner the adrenal glands are poorly demarcated from their surroundings. Again, CT provides a better view of the hyperplastic adrenal glands, which usually cannot be detected with ultrasound. Also the EUS on the left side shows the hyperplastic adrenal gland better than transcutaneous ultrasound. Differentiation to adenoma normally is only possible by histology or cytology (s.o. FNB).

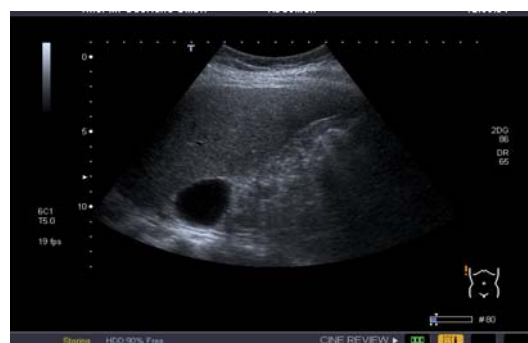Figure 7 EUS shows on left side an enlarged proximal shank of adrenal gland, which occurs in nodular hyperplasia.



Adrenal Cyst

A cyst of the adrenal region is anechoic, has smooth margins, and shows distal acoustic enhancement. Its extent is variable. True cysts have regular walls and are filled with serous material [Figure 8].

Figure 8 Round, sharply circumscribed, echo-free mass located dorsal to the right liver and cranial to the right kidney: adrenal cyst.



Most cystic masses in the adrenal region are secondary cysts that develop following pancreatitis, hemorrhage, or inflammation. Seldom cystic tumours like pheochromocytoma or lymphangioma are observed. The greater mobility of adrenal cysts serves to differentiate them from hepatic cysts in the right adrenal region. Lack of contact with the renal parenchyma distinguishes them from a cyst of the upper renal pole.

In the neighbourhood the followings are delineated for differentiation:

Renal cysts. Parietal cysts located in the upper pole of the kidney are particularly apt to be mistaken for adrenal cysts. They are distinguished by defining the relation of the cyst to the renal parenchyma.

Pancreatic pseudocysts and cystic pancreatic tumours. Pancreatic pseudocysts often form in the retroperitoneum following acute pancreatitis. The contents of the cysts may be completely anechoic, and the wall is usually irregular. Fine-needle aspiration (FNB) and laboratory analysis demonstrate high levels of pancreatic enzymes. Cystadenocarcinoma of the pancreas can also be a source of confusion.

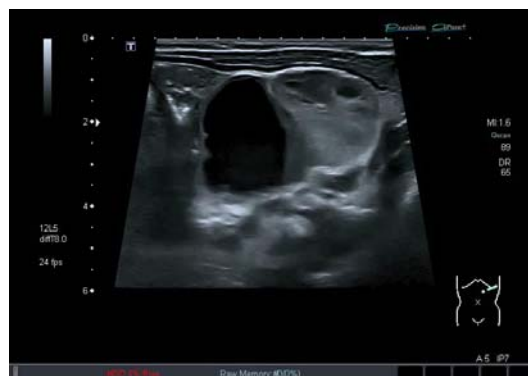Splenic and collateral vessels. Tortuous and ectatic splenic vessels can mimic a cystic mass in the adrenal region. Shunt vessels in portal hypertension, e.g. secondary to splenic vein thrombosis, can also assume bizarre shapes.

Intra-adrenal Hemorrhage (Hematoma)

Bleeding into an adrenal gland is anechoic in its early stage. It can occur in newborns due to obstetric trauma, hypoxia, or coagulation disorders. Intra-adrenal hemorrhage may correlate clinically with adrenal insufficiency. A large central hemorrhage (adrenal apoplexy) consistently leads to the marked enlargement of the gland [Figure 9]. An older hemorrhage becomes increasingly echogenic over time and may eventually be completely absorbed. Differentiation is required from partially cystic neuroblastomas in small children.

Up to 25% of patients who sustain blunt abdominal trauma are discovered to have hematomas in the adrenal region. They also occur in patients on anticoagulant medication and can lead to hypocortisolism (Addison disease).[(16)]

Figure 9 Echo -free intra-adrenal hemorrhage in a newborn with high resolution ultrasound



Adrenal Abscess

An abscess of the adrenal glands is rarely anechoic. It is usually hypoechoic or has a complex echo structure. When the contents are anechoic, the clinical and laboratory findings can differentiate the lesion from an ordinary cyst. The wall is irregular, and distal acoustic enhancement may be present

Cystic Tumour

A cystic tumour may be anechoic in rare cases, but usually it is hypoechoic. The walls are irregular in thickness and outline (some solid elements).

Differentiation of benign and malignant lesions

Benign adrenal gland tumours

Adenoma

Adenomas are uniformly hypoechoic with smooth margins and a round to oval shape, although some lesions have scalloped borders (polycyclic) [Figure 10-12]. Adenomas occasionally have an inhomogeneous appearance. Autopsy statistics indicate that they are quite common (10–20%), but most adenomas (90%) produce no endocrine symptoms, they are „silent“ and too small to be seen with ultrasound. The average size of adenomas in one study was 1.5 cm, although they may exceed 5 cm in diameter. In a small percentage of patients adenomas are bilateral. Functioning and nonfunctioning adenomas are indistinguishable by their sonographic features [(17-21)].

Figure 10 Medial to the upper pole of the right kidney is a sharply circumscribed, hypoechoic mass: typical adrenal adenoma.

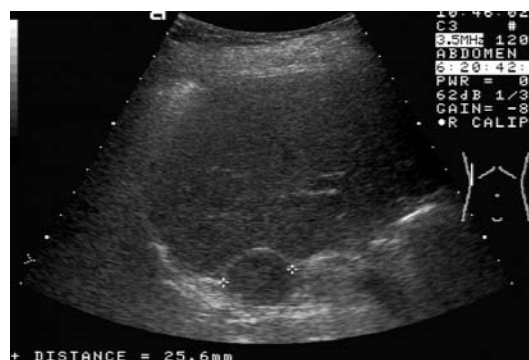


Figure 11 Hypoechoic, sharply circumscribed adenoma of the right adrenal gland discovered at routine ultrasound (confirmed by ultrasound-guided fine-needle aspiration).

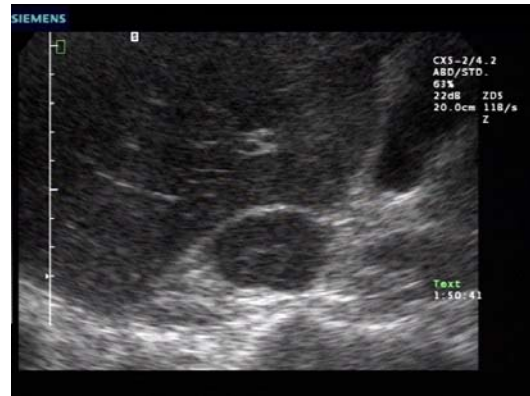
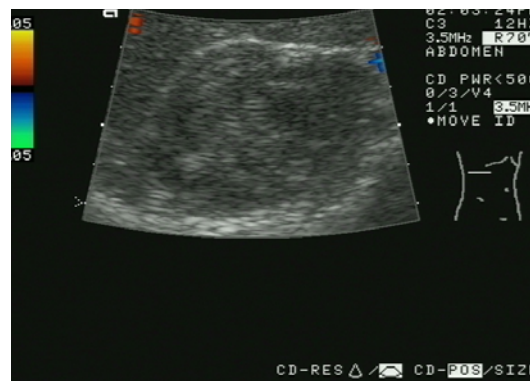
Figure 12 Approximately 5 cm hypoechoic inhomogenous mass above the right kidney: adenoma (incidentaloma) without associated symptoms, detected at routine upper abdominal ultrasound. Histology identified as an adrenal adenoma (most common incidentaloma).

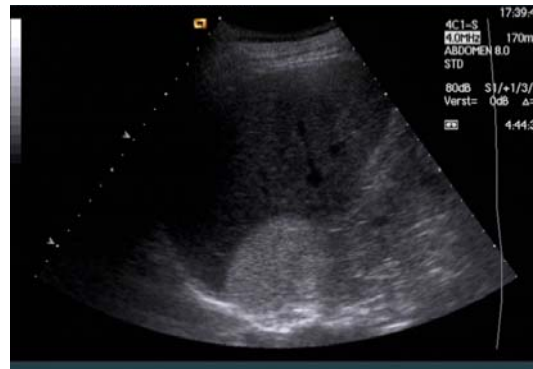

Lipoma, Myelolipoma

Lipoma. A pure lipoma of the adrenal glands has smooth margins and high, homogeneous echogenicity. In contrast to the mixed tissues of myolipoma, posterior acoustic shadowing does not occur. Lipoma is rare and shows no proliferative tendency.

Myelolipoma. Adrenal myelolipoma has smooth margins and a homogeneous hyperechoic structure [Figure 13]. It resembles a renal angiomyolipoma in its sonographic features. Posterior acoustic shadowing is often present. Malignant transformation is not known to occur. The tumour consists histologically of fat and bone marrow tissue (hematopoietic cells and reticular cells). Intratumoral hemorrhage and calcifications may be seen. [(22-25)]

Figure 13 Homogeneous, sharply circumscribed, hyperechoic tumour adjacent to the right kidney. Classic adrenal myelolipoma.



Calcification

Complete or partial calcification of the adrenal glands is characterized by a typical echo complex with a posterior acoustic shadow. Calcifications can result from a retained intra-adrenal hemorrhage or a prior inflammatory process (e.g., tuberculosis) [Figure 14]. Patients occasionally show the clinical manifestations of Addison disease. However, calcifications can also develop in tumours (carcinoma, metastases, pheochromocytoma, adenoma) [Figure 15].

Figure 14 In the proximal left kidney in the adrenal gland region we found a classical calcification with dorsal acoustic shadow.

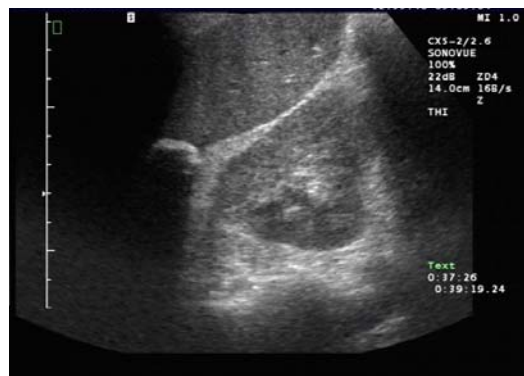
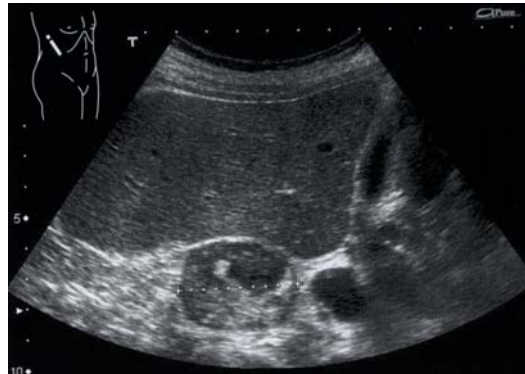
Figure 15 Small calcifications also occur in tumours of adrenal gland, most often observed in pheochromocytoma



Malignant adrenal gland tumours

Metastases

With their rich blood supply, the adrenal glands are the fourth most frequent site for hematogenous metastasis. Metastases to the adrenal glands account for the majority of solid adrenal tumours after the adenomas.

In contrast to adenomas these lesions are less homogeneous and often have irregular margins [Figure 16-18]. The most common primaries are bronchial carcinoma (25–30 %), breast carcinoma and malignant melanoma (in Europe). Other possible sources are gastrointestinal (esp. in Asia), urological and gynecological tumours (renal carcinoma, gastric carcinoma, pancreatic carcinoma and others). Adrenal metastases are bilateral in up to 30% of cases, and this can produce the clinical manifestations of Addison disease. Bronchial carcinoma is virtually the only tumour that is associated with isolated adrenal metastases (in ca. 15-20 %) [(26-28)].

Figure 16 Large metastasis from bronchial carcinoma on the right side, with a very inhomogeneous internal structure. Solid components are seen along with central liquid areas

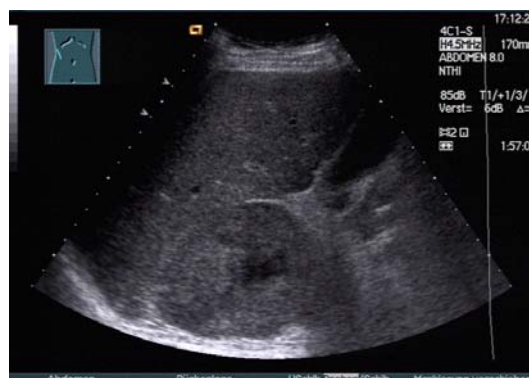

Figure 17 Transverse scan shows a metastasis with a complex echo structure “wedged” between right lobe of the liver, inferior vena cava, the kidney and spinal column.

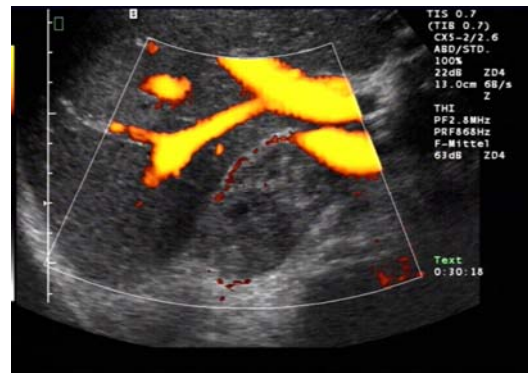
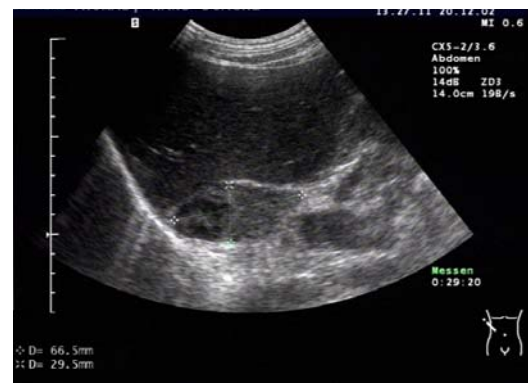
Figure 18 Transverse scan of a metastasis of the right adrenal gland with complex structure beside a primary tumour of lung cancer.



Pheochromocytoma

Pheochromocytoma is a tumour of the adrenal medulla that is generally detected sonographically (80–90% of cases) following the appearance of clinical symptoms (hypertension and tachycardia caused by increased catecholamine secretion).

Most pheochromocytomas are already several centimeters in diameter when diagnosed. They have smooth margins, a round shape, and a nonhomogeneous or complex echo structure.

Hypoechoic liquid components are also observed. A spectrum of appearances may be seen [Figure 19 and 20]. Pheochromocytomas are bilateral in approximately 10% of cases and extra-adrenal in 10–20%.

The “Zuckermandl organ” should be looked for at the level of the origin of the inferior mesenteric artery, anterior to the aorta.

Other extra-adrenal sites are the renal hilum, bladder wall, and thorax. Pheochromocytoma is occasionally seen posterior to the renal vein in transverse scans. Rarely, pheochromocytoma is diagnosed in the setting of multiple endocrine neoplasia (MEN). From 2% to 5% of pheochromocytomas are malignant. Owing to the risk of inciting a hypertensive crisis, fine-needle aspiration biopsy causes discrepant discussions about FNB [(29-44)].

Figure 19 Nonhomogeneous tumour with a hyperechoic center (positive endocrine test, increased catecholamine secretion) – phaeochromocytoma.

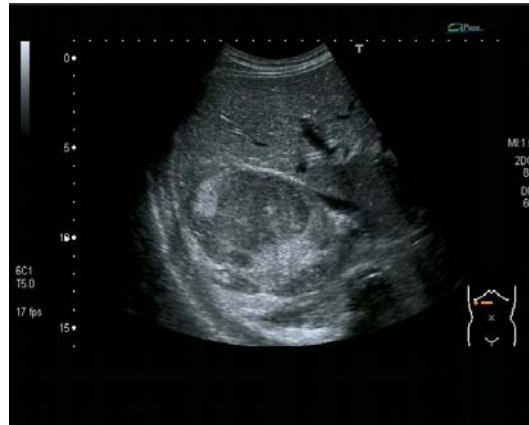
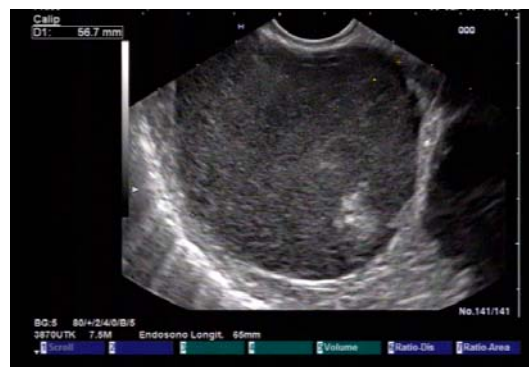
Figure 20 Large, functionally active pheochromocytoma (7 cm in diameter). The scan shows that most of tumour is hypoechoic with some hyperechoic regions.

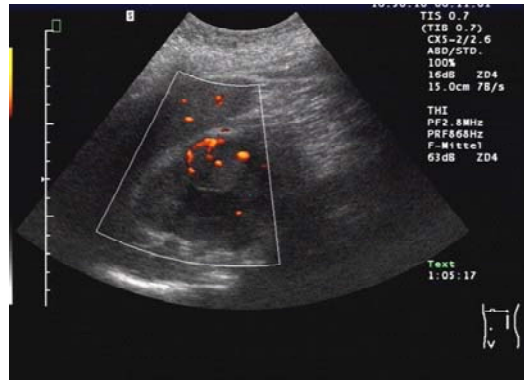

Lymphoma

The adrenal region is a rare extranodal site of occurrence for lymphoma. Foci of lymphomatous infiltration have smooth borders and are hypoechoic [Figure 21].

Differentiation is required from lymphomas in the renal or splenic hilum. If invasion by lymphoma is suspected, other nodal stations should be scanned and commonly infiltrated organs (spleen, liver) should be closely scrutinized. [(45-50)]

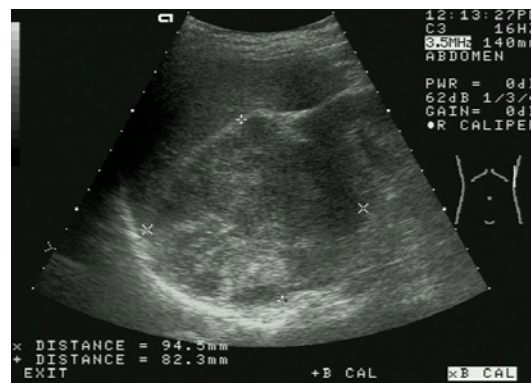
Figure 21 Perisplenic lymphoma in the left adrenal region of a patient with B-cell lymphoma. Colour Doppler shows hypervascularisation of the lymphatic tissue.



Adrenal Carcinoma

Adrenal carcinoma is usually inhomogeneous hypoechoic or echocomplex with irregular margins. It frequently infiltrates its surroundings and metastases can be demonstrated in the adrenal region and in other organs (e.g. the liver) [Figure 22]. The adrenal carcinoma is a very rare (1 : 1,7 million inhabitants), highly malignant tumour with a poor prognosis. Adrenal carcinoma is indistinguishable sonographically from a metastasis, although the visualization of additional tumours can advance the differential diagnosis. Most adrenal carcinomas are hormone-producing. Sometimes one can get evidence from detection of other tumour sign. The tumour is usually detected only after it has reached considerable size (often >8 cm). Intratumoural hemorrhage, necrotic foci, and calcifications may occur, adding to the variegated appearance. [(51)].

Figure 22 Adrenal carcinoma may be hypoechoic or may have a complex echo structure. Usually it was relatively large when diagnosed (in this case 8 cm × 9 cm) and had irregular margins.



Rare entities

Neuroblastoma

Neuroblastoma, like pheochromocytoma, develops from cells of the adrenal medulla. Besides the Wilms tumour, it is the most common malignant abdominal tumour in children. Approximately 70% of neuroblastomas are located in the adrenal glands, the rest occurring at other sites in the sympathetic chain. Most neuroblastomas are very large and predominantly hyperechoic. Some may have cystic elements (due to hemorrhage) and calcifications. Laboratory tests usually show an increase in catecholamine secretion.

Considerably less common are benign neural tumours such as ganglioneuromas. They have been described only sporadically in the adrenal glands, occurring more commonly in the posterior mediastinum and at paravertebral sites.

Other tumours

Incidentaloma

An incidentaloma is an adrenal tumour that is detected incidentally in an asymptomatic patient. Incidentalomas are found in 1% of CT examinations. They are much less common in ultrasound examinations, because of the difficulty in defining small lesions (< 2 cm) [Table 1 and 2; Figure 23 and 24]. The predominantly hypoechoic tumours listed in Table 1-2 account for the great majority of incidentalomas. Figure 25 [Figure 25] shows the algorithm used in the investigation of incidentalomas. Approximately 10% to 15% of these tumours are hormonally active. The recommended endocrine work-up is detailed in Table 3 [Table 3] [(52)]. In some cases, ultrasound-guided fine-needle aspiration can also aid in the evaluation of incidentalomas [Figure 26], but only ca. 1% to 2% of these tumours are malignant [(53-63)].

Figure 23 Abdominal ultrasound examination incidentally found most hypoechoic lesions smaller 2 cm without clinical symptoms – which is typical for incidentalomas

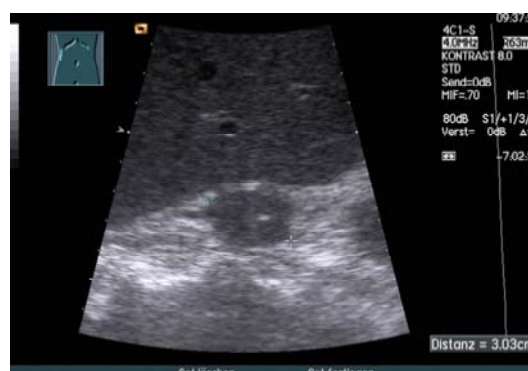

Figure 24 Adenomas occur most often among the incidentaloma of adrenal gland. They are smooth bordered and commonly homogeneous structured.

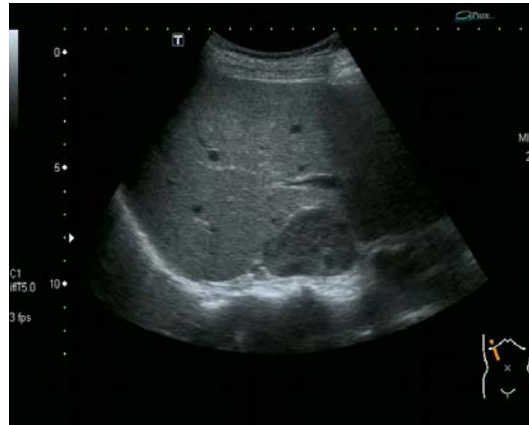

Table 1 Prevalence of adrenal gland-tumours in autopsy studies and CT-studies (after Reinke)[(61)]

Author	Year	Study	N	adrenal gland-Tumour %
Russi [(21)]	1944	autopsy, retrospective	9000	1.45
Commons [(17)]	1948	autopsy, retrospective	7437	2.86
Shamma [(64)]	1958	autopsy, retrospective	220	1.8
Kokko [(65)]	1967	autopsy, retrospective	1495	1.41
Hedeland [(66)]	1968	autopsy, prospective	739	8.7
Reinhard [(67)]	1994	autopsy, prospective	498	5.0
Total			19389	2.38
Glazer [(68)]	1982	CT, retrospective	2200	0.6
Garz [(68)]	1982	CT, retrospective	12000	0.5
Kley [(69)]	1990	CT, prospective	2568	4.4
Stark [(70)]	1994	CT, prospective	13818	0.8
Total			30586	1.0

Table 2 Pathological classification and prevalence of incidentalomas

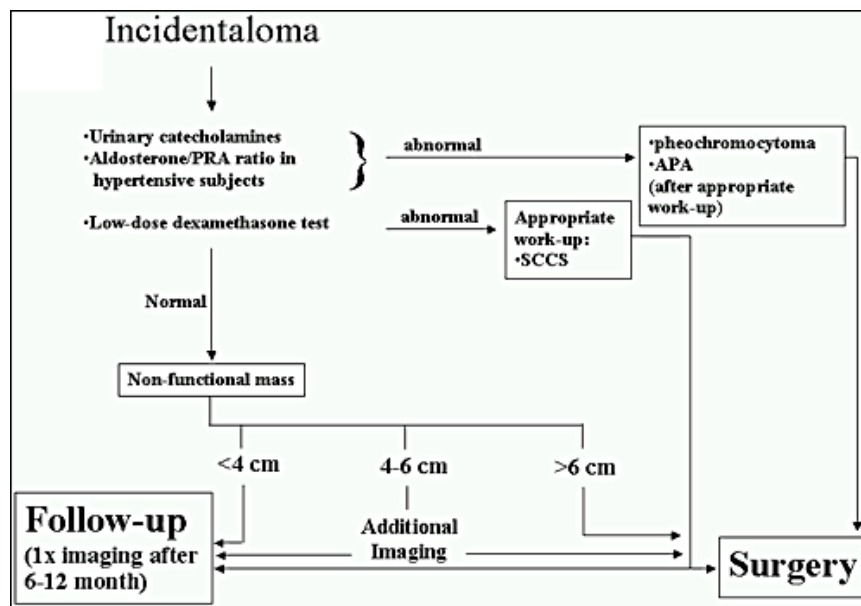
Diagnosis	Imaging + OP Reinke 1995 [(61)]	Imaging + OP Allolio 2001 [(53)]	OP Mantero 2000 [(71)]
[] Summery	n = 172	n = 267	n = 380
Adrenal adenoma	134 (78 %)	230 (86 %)	198 (52 %)
Nonfunctioning adrenal adenoma	119 (69 %)	206 (77 %)	137 (36 %)

Adrenal carcinoma	1	1 (0.3%)	47 (12 %)
Adrenal-hyperplasia	-	3	-
Pheochromocytoma	5 (3 %)	7 (2.6 %)	42 (11 %)
Ganglioneuroma	2	3 (1 %)	15 (4 %)
Myelolipoma	6 (3,5 %)	9 (3 %)	30 (8 %)
Adrenal cyst	5 (3 %)	6	20 (5 %)
Metastasis	1	3	7 (2 %)
other	2	5	21 (6 %)

Table 3 Endocrine laboratory work-up of adrenal incidentaloma (modif. after Reinke) [(61)]

Initial work-up	
Mandatory	<ul style="list-style-type: none"> ▶ Free catecholamines in 24 h urine ▶ Serum cortisol in dexamethasone suppression test (1 mg)
Optional	<ul style="list-style-type: none"> ▶ Plasma renin activity after 30 min rest period ▶ Potassium excretion in 24 h urine
Extended work-up if initial findings are abnormal	
Preclinical Cushing syndrome	<ul style="list-style-type: none"> ▶ High-dose dexamethasone suppression test (8 mg) ▶ CRH stimulation test
Conn syndrome	<ul style="list-style-type: none"> ▶ Aldosterone-18-glucuronide in 24 h urine ▶ Plasma renin activity and aldosterone at rest and orthostasis ▶ Selective renal vein catheterization with bilateral blood sampling for aldosterone and cortisol in adrenal venous blood

Figure 25 Algorithm for investigating an adrenal incidentaloma. Recommendations of the NIH state-of-the-science conference 2002. [(72)]



Ultrasound-guided Fine-needle Aspiration of an Adrenal Lesion

Given the frequency of incidentally detected adrenal tumours, every patient should undergo an initial endocrine work-up [Table 3]. If the tumour cannot be positively identified by laboratory tests and imaging (ultrasound, EUS, CT), ultrasound-guided fine-needle aspiration (UFNA) can supply a diagnosis in cases requiring treatment. The sensitivity of adrenal UFNA is between 90% and 95% [Table 4]. UFNA can provide material for cytological or histological analysis with a relatively low risk of complications. The procedure is performed in a lateral position. Access is easier in a right-sided lesion than in a left-sided one, also the complication rate is (somewhat) higher on the left side. UFNA is particularly indicated for the oncological investigation of tumours larger than 3 cm [Figure 26] [(9;73-94)].

Table 4 uFNB in adrenal glands tumours

Author	Year	N	Sensitivity	Specifity	Accuracy
Tikkakoski [(95)]	1991 c	56	91,3 %	97,0 %	85,7 %
Dock [(75)]	1992 c+h	47			85,1 %
Görg [(78)]	1992 h	37	95,2 %	100 %	97,0 %
Kojima [(96)]	1994 h	12	91,0 %		100 %
Fröhlich [(77)]	1995 c+h	33	88,2 %	92,9 %	90,3 %
Nürnberg [(97)]	1995 c+h	22	95,4 %	100 %	95,4 %
Lumachi [(98)]	2001 h	70	93,3 %	100 %	98,6 %
Liao [(99)]	2001 c+h	116	93,6 %		
Saeger [(100)]	2003 h	220	94,6 %	95,3 %	90,0 %
Kocijanic [(101)]	2004 c	64	90,0 %	100 %	91,0 %

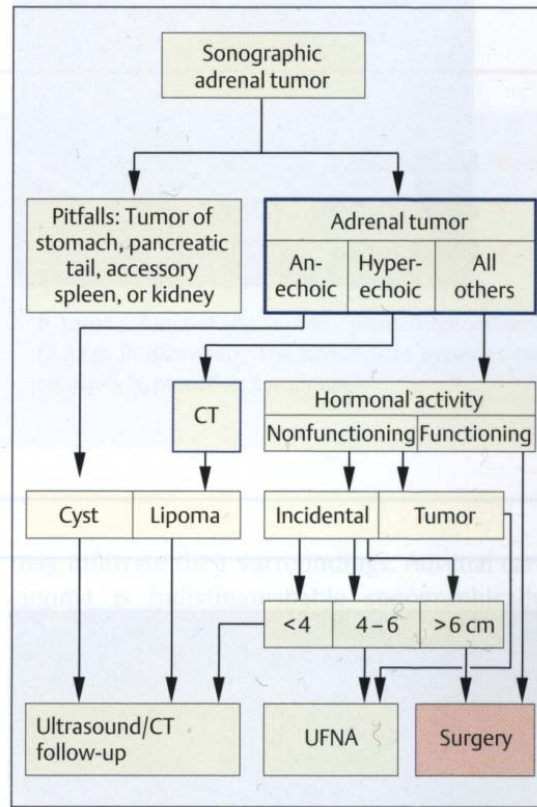
c=Cytology; h=Histology

Sensitivity: $RP \times 100 / (RP + FN) \%$

Spezifity: $RN \times 100 / (RN + FP) \%$

Accuracy: $(RP + RN) \times 100 / (RP + FP + RN + FN) \%$

Figure 26 Algorithm for “sonographic” adrenal tumours and the use of ultrasound-guided fine-needle aspiration (uFNA) (after Froehlich) [(77;102)]

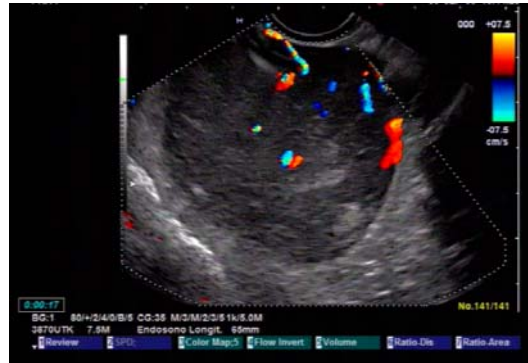

Special ultrasound techniques in differentiation of adrenal gland tumours

Colour Doppler imaging

Cysts do not show CD-signals, only in border areas, which also applies to hematoma or abscesses. Among tumours often lymphoma and endocrine tumours (pheochromocytoma) are hypervascularized [Figure 27]. Metastasis and carcinoma are regularly hypovascularized.

Figure 27 Some tumours show hypervascularization in CD, between them e.g. pheochromcytoma and lymphoma. Metastasis most are hypovascularized.



CEUS (Contrast enhanced ultrasound)

With help of CEUS cysts, abscesses and hematoma are to identify as avascular processes. Lipoma and myelolipoma regularly do not show a wash out effect [Figure 28]. Malignant tumours does not show a characteristic phenomenon, both wash out and late contrast accumulation occur [Figure 29]. The contrast media performance is inhomogeneous, e.g. also adenomas show a wash out phenomenon. Today, even after numerous studies it is not possible to exactly distinguish between benign (adenoma) and malignant tumours (metastasis) without histology or cytology.

Laparoscopic ultrasonography is used for better orientation in surgical area during laparoscopic surgeries because the most of surgeries of adrenal gland are performed by laparoscopic access [(103-112)].

Figure 28 In CEUS a myelolipoma shows a nearly constant contrast enhancement without wash out.

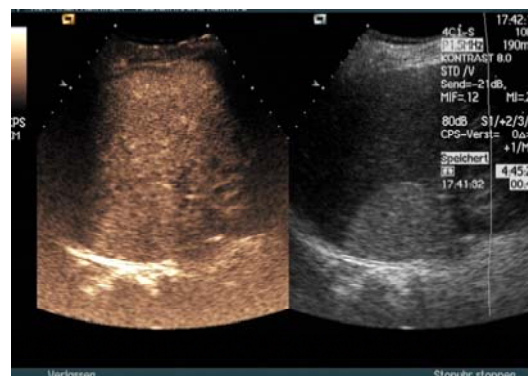
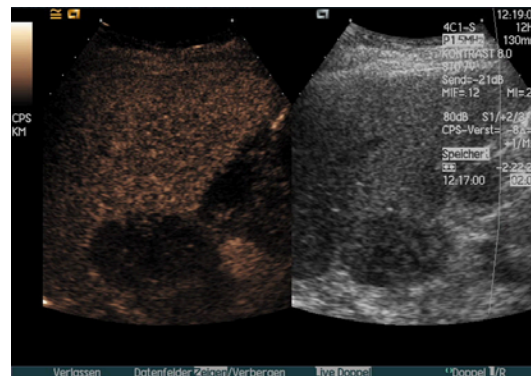


Figure 29 Partial metastases esp. of lung cancer, show a wash out of contrast media in late phase.



Clinical importance of adrenal glands ultrasound in daily routine

Sonography of the adrenal glands

- is able to show the normal adrenal gland ($ri > le$)
 - is very sensitive in detection of enlarged adrenal gland and especially adrenal gland tumours
 - is very sufficient in differentiation between cystic adrenal gland lesions and solid tumours
 - is limited in differentiation of solid tumours
 - is very useful in guidance for FNB (u/eusFNB)
 - often detects incidentaloma
 - is very helpful in the follow up of enlarged adrenal gland
 - EUS is the best imaging method for the examination of the left adrenal gland (as in FNB)
 - CEUS shows diversified results
- (see also Table 5 [Table 5].)

Indication for examination:

Ultrasonography of adrenal region should be a standard part of abdominal ultrasonography because a big part of pathologic changes is without any symptoms and early detection of them (especially of adrenal tumor) gives us better chance for therapy.

The number of patients with a so called Incidentaloma of adrenal gland (lesion up to 20mm) raises with increasing number of ultrasonographic examinations. The most of those lesions are benign and watchfull waiting (using ultrasound examinations) in cooperation with endocrinologists is usually sufficient.

Table 5 Sonographic features of adrenal diseases with or without endocrine symptoms (after Allolio et al.) [(53)]

	Sonographic appearance
Diseases with endocrine symptoms	
Addison disease	Adrenal atrophy not detectable with ultrasound; possible calcifications as evidence of prior tuberculosis
Conn disease	Unilateral adenomas, usually ≤ 2 cm, not detectable

Cushing syndrome	with ultrasound In 80% of cases, bilateral hyperplasia due to pituitary (75%) or paraneoplastic (5%) ACTH overproduction; hyperplasia is usually not detectable with ultrasound
Pheochromocytoma	Can be localized with ultrasound in 80–90% of cases; extra-adrenal location is difficult, usually prevents identification
Diseases without endocrine symptoms	
Adrenal adenoma	Most common solid mass
Adrenal carcinoma	Often quite large (several centimeters) despite absence of symptoms; sometimes detected incidentally at ultrasound
Adrenal metastases	Common with bronchial carcinoma, malignant lymphoma, breast cancer, renal cancer, pancreatic cancer, and melanoma
Adrenal tumours and cysts	Detectable at 1–1.5 cm on the right side, at 1.5–2 cm on the left side

Reference List

- (1) Jenssen C, Dietrich CF. Ultrasound and endoscopic ultrasound of the adrenal glands
1. Ultraschall Med 2010 Jun;31(3):228-47.
- (2) Nuernberg D. Nebennieren. In: Schmidt G., Greiner L., Nuernberg D., editors. Sonografische Differentialdiagnose. Stuttgart: Thieme; 2010.
- (3) Jenssen C., Schwenzer J., Siebert C., Wiegand A. Sonographie und Endosonographie der Nebennieren. Visions 2007;15(07):2-11.
- (4) Trojan J, Schwarz W, Sarrazin C, Thalhammer A, Vogl TJ, Dietrich CF. Role of ultrasonography in the detection of small adrenal masses. Ultraschall Med 2002 Apr;23(2):96-100.
- (5) Kann P, Hengstermann C, Heussel CP, Bittinger F, Engelbach M, Beyer J. Endosonography of the adrenal glands: normal size--pathological findings. Exp Clin Endocrinol Diabetes 1998;106(2):123-9.
- (6) Braun B. Nebennieren. In: Braun B., Günther R., Schwerk WB., editors. Ultraschalldiagnostik. Landshut: Ecomed; 1983.
- (7) Dietrich CF, Wehrmann T, Hoffmann C, Herrmann G, Caspary WF, Seifert H. Detection of the adrenal glands by endoscopic or transabdominal ultrasound. Endoscopy 1997 Nov;29(9):859-64.
- (8) Frentzel-Beyme B., Nuernberg D. Sonography of parathyroid and adrenal gland
1. Praxis (Bern 1994) 2006 May 3;95(18):737-40.

- (9) Nuernberg D. Ultrasound of adrenal gland tumours and indications for fine needle biopsy (uFNB). *Ultraschall Med* 2005 Dec;26(6):458-69.
- (10) Klingmuller V, Gurleyen N. Ultrasonic determination of the size of adrenal glands in newborn infants. *Ultraschall Med* 1997 Aug;18(4):169-73.
- (11) Leidig E. Sonography of adrenal gland diseases in the newborn infant
6. *Ultraschall Med* 1988 Aug;9(4):155-62.
- (12) Winkler P, Abel T, Helmke K. Sonographic imaging of normal adrenal glands in children and adolescents. An analysis of forms and reflex properties. *Ultraschall Med* 1987 Dec;8(6):271-7.
- (13) Nuernberg D. Nebennieren. In: Schmidt G., editor. *Sonografische Differentialdiagnose*. Stuttgart: Thieme; 2002.
- (14) Kann P, Hengstermann C, Heussel CP, Bittinger F, Engelbach M, Beyer J. Endosonography of the adrenal glands: normal size--pathological findings. *Exp Clin Endocrinol Diabetes* 1998;106(2):123-9.
- (15) Kann P, Bittinger F, Hengstermann C, Engelbach M, Beyer J. Endosonographic imaging of the adrenal glands: a new method. *Ultraschall Med* 1998 Feb;19(1):4-9.
- (16) Liessi G, Sandini F, Semisa M, Spaliviero B. Traumatic hematomas of the adrenal glands: CT and US findings in 3 cases. *Radiol Med* 1988 Dec;76(6):610-3.
- (17) COMMONS RR, CALLAWAY CP. Adenomas of the adrenal cortex
7. *Arch Med Interna* 1948 Jan;81(1):37-41.
- (18) Garz G, Luning M, Melzer B. Computed tomographic incidental finding of a hormone-inactive adrenal cortex adenoma
1. *Radiol Diagn (Berl)* 1985;26(6):761-6.
- (19) Moulton JS, Moulton JS. CT of the adrenal glands. *Semin Roentgenol* 1988 Oct;23(4):288-303.
- (20) Rezneck RH., Armstrong P. Imaging in endocrinology. The adrenal glands. *Clin Endocrinol (Oxf)* 1994;40(5):561-76.
- (21) RUSSI S, BLUMENTHAL HT, GRAY SH. Small adenomas of the adrenal cortex in hypertension and diabetes
2. *Arch Med Interna* 1945 Nov;76:284-91.
- (22) Okada K, Kojima M, Kamoi K, Watanabe H, Mitsuya H, Hayase Y. Two cases of adrenal myelolipoma diagnosed by ultrasonically guided percutaneous biopsy. *Hinyokika Kiyo* 1998 Jul;44(7):485-8.
- (23) Rao M. Adrenal myelolipoma
3. *Australas Radiol* 1992 May;36(2):172-3.

- (24) Rao P, Kenney PJ, Wagner BJ, Davidson AJ. Imaging and pathologic features of myelolipoma
2. Radiographics 1997 Nov;17(6):1373-85.
- (25) Robbani I, Shah I, Shah OJ. Diagnosis of adrenal myelolipoma by imaging and guided biopsy. Ceylon Med J 2003 Mar;48(1):24-5.
- (26) Fassnacht M, Kenn W, Allolio B. Adrenal tumors: how to establish malignancy ? J Endocrinol Invest 2004 Apr;27(4):387-99.
- (27) Lam KY, Lo CY. Metastatic tumours of the adrenal glands: a 30-year experience in a teaching hospital. Clin Endocrinol (Oxf) 2002 Jan;56(1):95-101.
- (28) Porte HL, Ernst OJ, Delebecq T, Metois D, Lemaitre LG, Wurtz AJ. Is computed tomography guided biopsy still necessary for the diagnosis of adrenal masses in patients with resectable non-small-cell lung cancer? Eur J Cardiothorac Surg 1999 May;15(5):597-601.
- (29) Andjelkovic Z., Tavcar I. Personal experience in diagnosis and localization of pheochromocytoma. Srp Arh Celok Lek 2002 Jul;130 Suppl 2:14-9.
- (30) Baguet J.P., Hammer L., Tremel F., Mangin L., Mallion J.M. Metastatic phaeochromocytoma: risks of diagnostic needle puncture and treatment by arterial embolisation. J Hum Hypertens 2001 Mar;15(3):209-11.
- (31) Baguet J.P., Hammer L., Mazzuco T.L., Chabre O., Mallion J.M., Sturm N., et al. Circumstances of discovery of phaeochromocytoma: a retrospective study of 41 consecutive patients. Eur J Endocrinol 2004 May;150(5):681-6.
- (32) Burton S., Ros PR. Adrenal Glands. In: Stark D., Bradley W., editors. Magnetic Resonance Imaging. Mosby; 1999.
- (33) Casola G, Nicolet V, vanSonnenberg E, Withers C, Bretagnolle M, Saba RM, et al. Unsuspected pheochromocytoma: risk of blood-pressure alterations during percutaneous adrenal biopsy
19. Radiology 1986 Jun;159(3):733-5.
- (34) Deodhare S, Chalvardjian A, Lata A, Marcuzzi D. Adrenal pheochromocytoma mimicking small cell carcinoma on fine needle aspiration biopsy. A case report. Acta Cytol 1996 Sep;40(5):1003-6.
- (35) Ford J, Rosenberg F, Chan N. Pheochromocytoma manifesting with shock presents a clinical paradox: a case report. CMAJ 1997 Oct 1;157(7):923-5.
- (36) Goldstein RE, O'Neill JA, Jr., Holcomb GW, III, Morgan WM, III, Neblett WW, III, Oates JA, et al. Clinical experience over 48 years with pheochromocytoma. Ann Surg 1999 Jun;229(6):755-64.
- (37) Hanna NN, Kenady DE. Hypertension in patients with pheochromocytoma. Curr Hypertens Rep 1999 Dec;1(6):540-5.

- (38) Jankovic R, Diklic A, Paunovic I, Krgovic K, Hivaljevic V, Todorovic-Kazic M, et al. Results of surgical treatment of pheochromocytoma at the Institute of Endocrinology of the Clinical Center of Serbia in Belgrade]. *Srp Arh Celok Lek* 2002 Jul;130 Suppl 2:38-42.
- (39) Kann PH, Wirkus B, Behr T, Klose KJ, Meyer S. Endosonographic imaging of benign and malignant pheochromocytomas. *J Clin Endocrinol Metab* 2004 Apr;89(4):1694-7.
- (40) Kebebew E, Duh QY. Benign and malignant pheochromocytoma: diagnosis, treatment, and follow-Up. *Surg Oncol Clin N Am* 1998 Oct;7(4):765-89.
- (41) Kudva YC, Sawka AM, Young WF, Jr. Clinical review 164: The laboratory diagnosis of adrenal pheochromocytoma: the Mayo Clinic experience. *J Clin Endocrinol Metab* 2003 Oct;88(10):4533-9.
- (42) Liu G, Qiang W, Zhang H, Yang C. Clinical types of pheochromocytom. *Zhonghua Wai Ke Za Zhi* 2000 Feb;38(2):122-4.
- (43) O'Halloran T, McGreal G, McDermott E, O'Higgins N. 47 years of phaeochromocytomas. *Ir Med J* 2001 Jul;94(7):200-3.
- (44) Schwerk WB, Gorg C, Gorg K, Restrepo IK. Adrenal pheochromocytomas: a broad spectrum of sonographic presentation. *J Ultrasound Med* 1994 Jul;13(7):517-21.
- (45) Dahami Z, Debbagh A, Dakir M, Hafiani M, Joual A, Bennani S, et al. Phenotype B primitive adrenal lymphoma, diagnosed by percutaneous aspiration biopsy. *Ann Urol (Paris)* 2001 Jan;35(1):22-5.
- (46) Erdogan G, Gullu S, Colak T, Kamel AN, Baskal N, Ekinici C. Non-Hodgkin's lymphoma presenting as thyroid and adrenal gland involvement. *Endocr J* 1997 Feb;44(1):199-203.
- (47) Khader A, Galgani P, Ludivici M, Michelotti R, Benvenuti F. Bilateral adrenal lymphoma. A case report. *Minerva Chir* 1997 Dec;52(12):1523-5.
- (48) Lee DH, Park JH, Lee JJ, Chung IJ, Chung DJ, Chung MY, et al. Non-Hodgkin's lymphoma of the thyroid and adrenal glands. *Korean J Intern Med* 2000 Jan;15(1):76-80.
- (49) Nishikawa N, Yamamoto S, Kouhei N, Nishiyama H, Moroi S, Kamoto T, et al. A case of malignant lymphoma with bilateral adrenal involvement. *Hinyokika Kiyo* 2003 Dec;49(12):749-51.
- (50) Takai K, Hiragino T, Isoyama R, Takahashi M, Naito K. A case of primary adrenal lymphoma diagnosed from percutaneous needle biopsy. *Urol Int* 1999;62(1):31-3.
- (51) Lorusso GD, Sarwar SF, Sarma DP, Restrepo S, Palacios E. Synchronous adrenal cortical carcinoma in a patient with lung cancer. *J La State Med Soc* 2004 Jan;156(1):37-9.

- (52) Lehnert H., Allolio B., Buhr HJ., Hahn K., Mohnike K., Weiss M. Nebenniere. In: Lehnert H., editor. Rationelle Diagnostik und Therapie in Endokrinologie, Diabetologie und Stoffwechsel. Stuttgart: Thieme; 2003. p. 137-80.
- (53) Allolio B. Adrenal Incidentalomas. In: Margioris AN, editor. Adrenal Disorders. Totowa: Human Press Inc.; 2001. p. 249-61.
- (54) Alves A., Scatton O., Dousset B. Diagnostic and therapeutic strategy for an incidental finding of an adrenal mass. J Chir (Paris) 2002 Sep;139(4):205-13.
- (55) Arnaldi G., Masini AM., Giacchetti G., Taccaliti A., Faloia E., Mantero F. Adrenal incidentaloma. Braz J Med Biol Res 2000 Oct;33(10):1177-89.
- (56) Barzon L., Scaroni C., Sonino N., Fallo F., Paoletta A., Boscaro M. Risk factors and long-term follow-up of adrenal incidentalomas
24. J Clin Endocrinol Metab 1999 Feb;84(2):520-6.
- (57) Grumbach MM., Biller BM., Braunstein GD., Campbell KK., Carney JA., Godley PA., et al. Management of the clinically inapparent adrenal mass ("incidentaloma"). Ann Intern Med 2003 Mar 4;138(5):424-9.
- (58) Heintz A., Junginger T., Beyer J., Kann P., Jarusch-Hancke C., Niemann U. Das Inzidentalom der Nebenniere. Dt Aertzblatt 2001;98(18):1008-12.
- (59) Hensen J., Harsch I., Sachse R., Pavel M., Rico AF, Walter M, et al. Adrenal gland incidentaloma is not a "time bomb"--arguments for follow-up control
1. Zentralbl Chir 1997;122(6):487-93.
- (60) Mantero F, Masini AM, Opocher G, Giovagnetti M, Arnaldi G. Adrenal incidentaloma: an overview of hormonal data from the National Italian Study Group. Horm Res 1997;47(4-6):284-9.
- (61) Reincke M., Allolio B. Das Nebenniereninzidentalom: Die Kunst der Beschränkung in Diagnostik und Therapie. Dt Aertzblatt 1995;92:764-70.
- (62) Slawik M., Reincke M. Adrenal Incidentalomas. 2003.
Ref Type: Data File
- (63) Young WF, Jr. Management approaches to adrenal incidentalomas. A view from Rochester, Minnesota. Endocrinol Metab Clin North Am 2000 Mar;29(1):159-85, x.
- (64) SHAMMA AH, GODDARD JW, SOMMERS SC. A study of the adrenal status in hypertension
2. J Chronic Dis 1958 Nov;8(5):587-95.
- (65) Kokko JP, Brown TC, Berman MM. Adrenal adenoma and hypertension
1. Lancet 1967 Mar 4;1(7488):468-70.
- (66) Hedeland H, Ostberg G, Hokfelt B. On the prevalence of adrenocortical adenomas in an autopsy material in relation to hypertension and diabetes
1. Acta Med Scand 1968 Sep;184(3):211-4.

- (67) Reinhard C., Schubert B. Nodules and adenomas in the adrenal cortex: Incidence in post-mortem series and correlation with clinical data. *Exp Clin Endocrinol Suppl* 1994;1:192.
- (68) Glazer HS, Weyman PJ, Sagel SS, Levitt RG, McClennan BL. Nonfunctioning adrenal masses: incidental discovery on computed tomography 32. *AJR Am J Roentgenol* 1982 Jul;139(1):81-5.
- (69) Kley HK., Jaresch S., Jungblut R., Schlaghecke R. Endokrin inaktive Nebennierentumoren. In: Allolio B, editor. *Moderne Diagnostik und therapeutische Strategien bei Nebennierenerkrankungen*. Schattauer; 1990. p. 189-97.
- (70) Stark S., Sachse R., Cidlinski K., Riel R., Hahn EG., Dörr HG., et al. Endocrine inactive adrenocortical adenomas (ACA) are a condition of the elderly. *Exp Clin Endocrinol Suppl* 1994;1:193.
- (71) Mantero F, Terzolo M, Arnaldi G, Osella G, Masini AM, Ali A, et al. A survey on adrenal incidentaloma in Italy. Study Group on Adrenal Tumors of the Italian Society of Endocrinology. *J Clin Endocrinol Metab* 2000 Feb;85(2):637-44.
- (72) Management of the Clinically Inapparent Adrenal Mass ("Incidentaloma"): of the House Comm. on National Institute of Health (NIH), State-of-the-science Conference Statement, (2002).
- (73) Chang KJ, Erickson RA, Nguyen P. Endoscopic ultrasound (EUS) and EUS-guided fine-needle aspiration of the left adrenal gland. *Gastrointest Endosc* 1996 Nov;44(5):568-72.
- (74) Chhieng DC, Jhala D, Jhala N, Eltoun I, Chen VK, Vickers S, et al. Endoscopic ultrasound-guided fine-needle aspiration biopsy: a study of 103 cases. *Cancer* 2002 Aug 25;96(4):232-9.
- (75) Dock W, Grabenwoeger F, Schurawitzki H, Wittich GR, Mostbeck G, Karnel F, et al. The technic of adrenal biopsy. Ultrasound versus CT as the guidance method. *Rofo* 1992 Oct;157(4):344-8.
- (76) Eloubeidi MA, Seewald S, Tamhane A, Brand B, Chen VK, Yasuda I, et al. EUS-guided FNA of the left adrenal gland in patients with thoracic or GI malignancies. *Gastrointest Endosc* 2004 May;59(6):627-33.
- (77) Froehlich E, Ruffle W, Strunk H, Stuckmann G, Seeliger H. The value of fine needle puncture in adrenal gland tumors 1. *Ultraschall Med* 1995 Apr;16(2):90-3.
- (78) Goerg C, Schwerek WB, Bittinger A, Euer B, Gorg K. Sonographically guided fine-needle puncture of adrenal tumors. *Dtsch Med Wochenschr* 1992 Mar 20;117(12):448-54.
- (79) Goerg C, Schwerek WB, Wolf M, Havemann K. Adrenal masses in lung cancer: sonographic diagnosis and follow-up. *Eur J Cancer* 1992;28A(8-9):1400-3.

- (80) Harisinghani MG., Maher MM., Hahn PF., Gervais DA., Jhaveri K., Varghese J., et al. Predictive value of benign percutaneous adrenal biopsies in oncology patients. *Clin Radiol* 2002 Oct;57(10):898-901.
- (81) Jaeger HJ, MacFie J, Mitchell CJ, Couse N, Wai D. Diagnosis of abdominal masses with percutaneous biopsy guided by ultrasound. *BMJ* 1990 Nov 24;301(6762):1188-91.
- (82) Jhala NC, Jhala D, Eloubeidi MA, Chhieng DC, Crowe DR, Roberson J, et al. Endoscopic ultrasound-guided fine-needle aspiration biopsy of the adrenal glands: analysis of 24 patients. *Cancer* 2004 Oct 25;102(5):308-14.
- (83) Karstrup S, Torp-Pedersen S, Nolsoe C, Horn T, Hegedus L. Ultrasonically guided fine-needle biopsies from adrenal tumors. *Scand J Urol Nephrol Suppl* 1991;137:31-4.
- (84) Liessi G, Sandini F, Spaliviero B, Sartori F, Sabbadin P, Barbazza R. CT-guided percutaneous biopsy of adrenal masses. Experience of the technic in 54 neoplasm patients. *Radiol Med* 1990 Apr;79(4):366-70.
- (85) McCorkell SJ, Niles NL. Fine-needle aspiration of catecholamine-producing adrenal masses: a possibly fatal mistake
1. *AJR Am J Roentgenol* 1985 Jul;145(1):113-4.
- (86) Meyer S, Bittinger F, Keth A, Von Mach MA, Kann PH. Endosonographically controlled transluminal fine needle aspiration biopsy: diagnostic quality by cytologic and histopathologic classification]. *Dtsch Med Wochenschr* 2003 Jul 25;128(30):1585-91.
- (87) Mody MK, Kazerooni EA, Korobkin M. Percutaneous CT-guided biopsy of adrenal masses: immediate and delayed complications. *J Comput Assist Tomogr* 1995 May;19(3):434-9.
- (88) Paulsen SD, Nghiem HV, Korobkin M, Caoili EM, Higgins EJ. Changing role of imaging-guided percutaneous biopsy of adrenal masses: evaluation of 50 adrenal biopsies. *AJR Am J Roentgenol* 2004 Apr;182(4):1033-7.
- (89) Saboorian MH, Katz RL, Charnsangavej C. Fine needle aspiration cytology of primary and metastatic lesions of the adrenal gland. A series of 188 biopsies with radiologic correlation. *Acta Cytol* 1995 Sep;39(5):843-51.
- (90) Sudhoff T, Hollerbach S, Wilhelms I, Willert J, Reiser M, Topalidis T, et al. Clinical utility of EUS-FNA in upper gastrointestinal and mediastinal disease. *Dtsch Med Wochenschr* 2004 Oct 15;129(42):2227-32.
- (91) Varadarajulu S, Fraig M, Schmulewitz N, Roberts S, Wildi S, Hawes RH, et al. Comparison of EUS-guided 19-gauge Trucut needle biopsy with EUS-guided fine-needle aspiration. *Endoscopy* 2004 May;36(5):397-401.
- (92) Voit C, Kron M, Schafer G, Schoengen A, Audring H, Lukowsky A, et al. Ultrasound-guided fine needle aspiration cytology prior to sentinel lymph node biopsy in melanoma patients. *Ann Surg Oncol* 2006 Dec;13(12):1682-9.

- (93) Weiss H, Duntsch U, Weiss A. Risks of fine needle puncture--results of a survey in West Germany(German Society of Ultrasound in Medicinesurvey)]. *Ultraschall Med* 1988 Jun;9(3):121-7.
- (94) Weiss H, Duntsch U. Complications of fine needle puncture. DEGUM survey II. *Ultraschall Med* 1996 Jun;17(3):118-30.
- (95) Tikkakoski T, Taavitsainen M, Paivansalo M, Lahde S, paja-Sarkkinen M. Accuracy of adrenal biopsy guided by ultrasound and CT. *Acta Radiol* 1991 Sep;32(5):371-4.
- (96) Kojima M, Saitoh M, Itoh H, Ukimura O, Ohe H, Watanabe H. Percutaneous biopsy for adrenal tumors using ultrasonically guided puncture. *Tohoku J Exp Med* 1994 Apr;172(4):333-43.
- (97) Nuernberg D., Loeschner C., Jung A. Entwicklung der bildgebenden Diagnostik und Stellenwert der ultraschallgezielten Feinnadelpunktion (uFNP) in der Onkologie. *Abstratctband Dt Krebsskongress 2002* 2002;685.
- (98) Lumachi F, Borsato S, Brandes AA, Boccagni P, Tregnaghi A, Angelini F, et al. Fine-needle aspiration cytology of adrenal masses in noncancer patients: clinicoradiologic and histologic correlations in functioning and nonfunctioning tumors. *Cancer* 2001 Oct 25;93(5):323-9.
- (99) Liao JT, Huang TH, Wu BY. Ultrasonographic evaluation of adrenal masses. *Hunan Yi Ke Da Xue Xue Bao* 2001 Oct 28;26(5):453-4.
- (100) Saeger W, Fassnacht M, Chita R, Prager G, Nies C, Lorenz K, et al. High diagnostic accuracy of adrenal core biopsy: results of the German and Austrian adrenal network multicenter trial in 220 consecutive patients. *Hum Pathol* 2003 Feb;34(2):180-6.
- (101) Kocijancic K, Kocijancic I, Guna F. Role of sonographically guided fine-needle aspiration biopsy of adrenal masses in patients with lung cancer. *J Clin Ultrasound* 2004 Jan;32(1):12-6.
- (102) Strunk H, Frohlich E, Thelen M. Ultrasound-proven adrenal gland tumor. References for diagnostic management. *Fortschr Med* 1992 Mar 20;110(8):122-5.
- (103) Fahlenkamp D, Beer M, Schonberger B, Lein M, Turk I, Loening SA. Laparoscopic adrenalectomy. *Tech Urol* 1996;2(1):48-53.
- (104) Filipponi S, Guerrieri M, Arnaldi G, Giovagnetti M, Masini AM, Lezoche E, et al. Laparoscopic adrenalectomy: a report on 50 operations. *Eur J Endocrinol* 1998 May;138(5):548-53.
- (105) Fletcher DR, Beiles CB, Hardy KJ. Laparoscopic adrenalectomy
1. *Aust N Z J Surg* 1994 Jun;64(6):427-30.
- (106) Imai T, Kikumori T, Shibata A, Fujiwara M, Hibi Y, Nakao A. Laparoscopic adrenalectomy for incidentaloma and bilateral adrenal disease. *Asian J Surg* 2003 Apr;26(2):64-70.

- (107) Kebebew E, Siperstein AE, Duh QY. Laparoscopic adrenalectomy: the optimal surgical approach. *J Laparoendosc Adv Surg Tech A* 2001 Dec;11(6):409-13.
- (108) Kebebew E, Siperstein AE, Clark OH, Duh QY. Results of laparoscopic adrenalectomy for suspected and unsuspected malignant adrenal neoplasms. *Arch Surg* 2002 Aug;137(8):948-51.
- (109) Kebebew E, Siperstein AE, Clark OH, Duh QY. Results of laparoscopic adrenalectomy for suspected and unsuspected malignant adrenal neoplasms. *Arch Surg* 2002 Aug;137(8):948-51.
- (110) Napoli N, Romano G, Carini F, Lo Monte AI, Calderone F, Di LR, et al. Laparoscopic adrenalectomy: our preliminary experience. *G Chir* 2004 Jun;25(6-7):238-41.
- (111) Saunders BD, Doherty GM. Laparoscopic adrenalectomy for malignant disease. *Lancet Oncol* 2004 Dec;5(12):718-26.
- (112) Tsuru N, Ushiyama T, Suzuki K. Laparoscopic adrenalectomy for primary and secondary malignant adrenal tumors. *J Endourol* 2005 Jul;19(6):702-8.