

# **EFSUMB Course Book**

## **Student Edition**

**Editors: Jan Tuma, Radu Badea, Christoph F. Dietrich**

### *Ultrasound of the gastrointestinal tract*

**Klaus Dirks<sup>1</sup>, Alois Hollerweger<sup>2</sup>**

<sup>1</sup>Caritas-Krankenhaus Bad Mergentheim, Germany

<sup>2</sup>Krankenhaus Barmherzige Brüder, Salzburg, Austria

**Corresponding author:**

Dr. Klaus Dirks  
Interdisziplinäre Ultraschallabteilung  
Rems-Murr-Klinikum Winnenden  
Am Jakobsweg 1  
D-71364 Winnenden  
Tel.: (+) 49 - 7195 - 591 - 0  
Email: [kdirks@khrmk.de](mailto:kdirks@khrmk.de)

## Content

Content .....	2
Introduction.....	2
Examination technique .....	3
Patient preparation.....	3
Patient positioning and systematic examination.....	3
Graded compression.....	3
Approach to the patient.....	4
Transducer selection.....	4
Additional techniques.....	5
Settings of the ultrasonic machine .....	6
Anatomy and systematic examination technique.....	6
Gastrointestinal wall layers .....	7
Oesophagus.....	8
Stomach, Duodenum .....	9
Small bowel.....	10
Colon.....	10
Normal findings and its variants.....	11
Stomach.....	11
Duodenum, small bowel.....	13
Colon.....	15
Appendix.....	16
Lymph nodes .....	17
Additional evaluation criteria .....	17
VIP: Very Important (and most frequent) Pathologies .....	17
Acute Appendicitis .....	17
Diverticulitis.....	20
Bowel obstruction.....	22
Gastric outlet and duodenal obstruction .....	22
Small bowel obstruction.....	23
Large bowel obstruction .....	25
Chronic inflammatory bowel disease (CIBD).....	27
Crohn's disease.....	27
Ulcerative colitis .....	29
Neoplastic disease.....	30
Gastric tumours .....	30
Tumours of the small bowel.....	32
Tumours of the colon.....	32
GI ultrasound in clinical practice .....	34
Recommended reading .....	34

## Introduction

For many years the gastrointestinal tract (GI tract) was rather a troublemaker than a target of the abdominal ultrasound examination. Gas and ingesta are known as

particular enemies of ultrasound and in many cases even obstruct the examination of other abdominal organs (e.g. of the aorta or retroperitoneal lymph nodes).

Today this has changed completely: ultrasound in Europe has found its place in gastrointestinal examination methods as well as endoscopy or MRI techniques. In addition to endoscopy or conventional contrast radiography US provides detailed information on bowel wall layers and its surroundings. Sonography at the same time gives us fascinating real time insights in bowel function.

Meanwhile ultrasound of the GI-tract has become a routine procedure in many emergency rooms after the physical examination. Leading questions are acute conditions such as appendicitis, diverticulitis, or bowel obstruction but also a number of subacute and chronic diseases.

Sonography of the GI-tract actually seems more difficult than sonography of the liver or gall bladder, nevertheless it should be included in abdominal US examinations from the early beginning. In many cases pathological findings like appendicitis or diverticulitis are even easier to detect than normal bowel structures.

## **Examination technique**

### **Patient preparation**

In contrast to the examination of the gall bladder or the pancreas an overnight period of fasting prior to examination is not necessary in all cases. For graduation of stenosis e.g. in Crohn's disease a normal filled GI tract even is favourable. Routine use of dimeticon was established in all abdominal ultrasound examinations in the beginning, but is not necessary even not in examination of the GI tract.

Emergency examinations have to be carried out without consideration of the status of the filling the bowel. In our experience the wide availability and the lack of need for any preparation is one of the great advantages of sonography.

Only focused studies of the stomach wall are done first with an empty organ. Some times in a second step the stomach is filled with clear water to get a better distension (technique of fluid filled stomach).

### **Patient positioning and systematic examination**

Examination of the GI tract is carried out in a comfortable supine position. Rotation to a left or right lateral position or standing up is only necessary in very special questions of gastric disorders.

In order to avoid interfering bowel gas in cases of bowel obstruction, it is recommended to access the abdomen from a more lateral point of view through both flanks. In this cases a slightly oblique patient's position makes the transducers application easier.

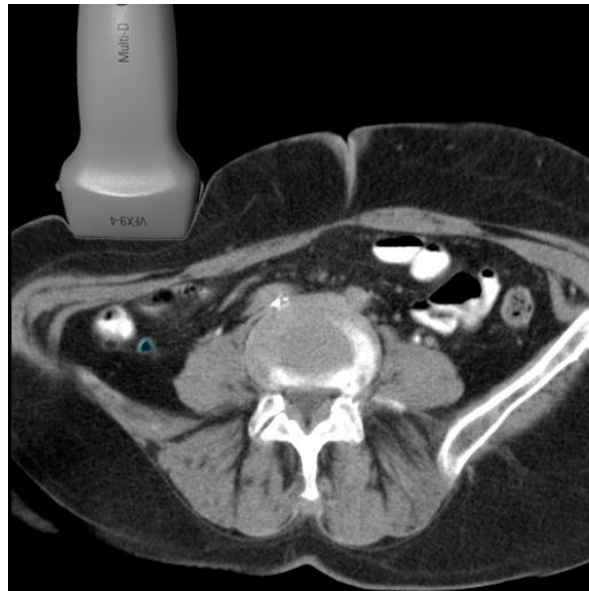Proceedings concerning a systematic examination of the GI tract are described in the anatomic remarks below.

### **Graded compression**

Careful but resolute compression with the transducer eliminates gas, abdominal fat and interfering bowel loops by slightly pressing them aside. Because of limited penetration depth compression is helpful particularly in using the linear probe. In

many cases only so called “graded compression” makes it possible to identify, for example, the appendix [Figure 1].

**Figure 1 Graded compression with the linear probe in a schematic CT scan: fat, gas and interfering bowel loops are pressed aside. The distance to blue marked appendix in this way is shortened.**



### Approach to the patient

In contrast to CT, ultrasound keeps you in direct contact with your patient. In patients with acute abdominal pain that is both a burden and an opportunity. Always firstly inform your patient that a little compression will be necessary, but he has to tell you when it gets to painful.

Many emergency patients could point out the spot of maximum pain with one finger: Putting the transducer just in this place and compressing carefully you often can make a one look diagnosis of appendicitis or diverticulitis.

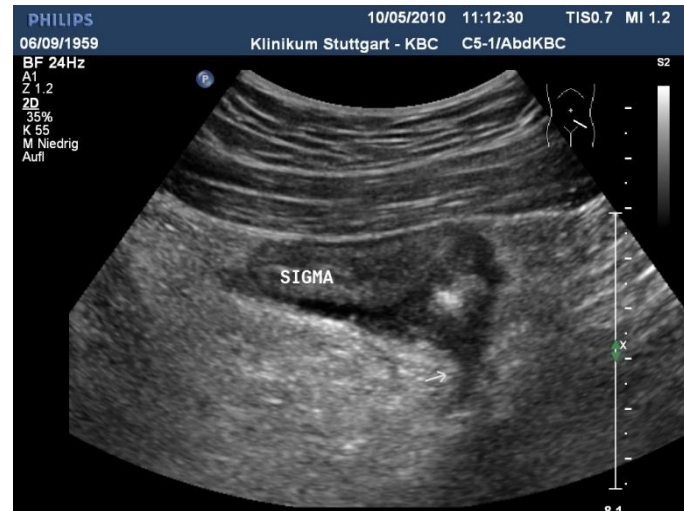Nevertheless a short systematic examination of the rest of GI tract and even the other abdominal organs should never remain undone.

### Transducer selection

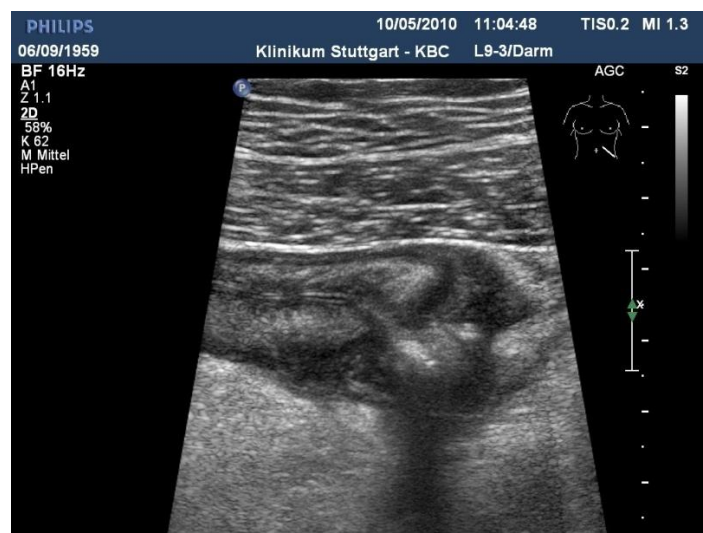For gaining a first overview of the alimentary tract conventional curved abdominal probes (2-5 MHz) are the method of choice. As mentioned above with this probe you always should have a look at the rest of abdominal organs.

In a second step conspicuous parts of the GI tract or the area of maximum pain are investigated with a high-frequency linear probe (5 to 15 MHz). These linear transducers can identify many more details and may distinguish different layers of the wall. The handicap of high-frequency linear probes may be a minor penetration depth. But this problem has been improved in modern ultrasound machines, so you may get problems only in very obese patients. Make it a rule always at least to try the linear probe when examining the GI tract! [Figure 2 and 3].

**Figure 2 Sigmoid diverticulitis. First overview with the curved array (1-5 MHz) identifies the area of interest. Also deeper localized parts of bowel can be evaluated.**



**Figure 3 Sigmoid diverticulitis (same patient as figure 2). Details with the linear array (3-9MHz): The thickened layers of the colon wall and protuberance of the diverticulum can be recognized. Around the diverticulum you find a small hypoechoic rim and surrounding hyperechoic fatty tissue.**



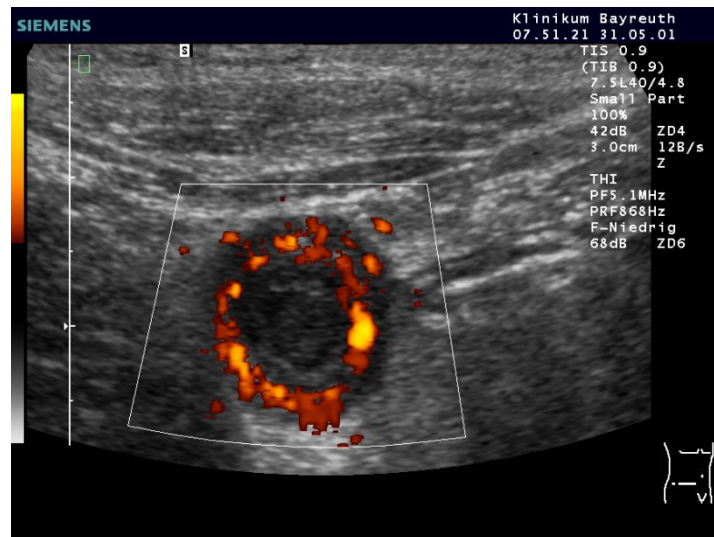
### Additional techniques

Tissue harmonic imaging often allows better delineation of the different layers of the wall. But the additional effect depends very much on the US machine being used. Modern technical equipment also includes Colour Doppler imaging. The utility of Colour Doppler imaging has been described in a variety of gastrointestinal disorders,



particularly in patients with Crohn's disease, ischemic disease, and so on [Figure 4]. Both information of the main mesenteric vessels (systolic and diastolic velocities, resistance index) and information on end-organ vascularity in the affected segments of the gastrointestinal tract may contribute to a correct diagnosis. But technical influences have to be considered, e.g. depth penetration, pressure and equipment used.

**Figure 4 Colour Doppler (power mode) in an acute appendicitis (target sign), showing increased vascularisation in the inflamed appendix.**



Endoscopic ultrasound (transoral, transrectal or transvaginal) can be used complementary for further evaluation of intestinal diseases. Contrast enhanced ultrasound (CEUS) and the upcoming elastographic techniques details are not part of this introduction.

Perineal ultrasound is another technique that can provide detailed information about perianal structures. This approach is particularly helpful in the initial evaluation of patients with perianal fistulas.

### Settings of the ultrasonic machine

Using the curved array you can use a common abdominal preset. Transducer frequency should be selected as high as possible. Whenever available the linear transducer should be given a trial. Modern linear transducers have an improved penetration and can be used in most adults. If you have no bowel preset for your linear transducer you can achieve proper results with your thyroid preset.

### Anatomy and systematic examination technique

Human GI tract is an up to 9 metres long tube from our mouth to the anus. Only parts of it could be displayed by sonography. How much of it you can evaluate, strongly depends on your personal experience and individual conditions e.g. intestinal gas, obesity et cetera.

Certain parts of the gut such as the cardia, the gastric antrum, the duodenum, the ileocecal region, the ascending and descending colon can be displayed routinely. Other parts such as the rectum, the lower sigmoid colon, and the left colonic flexure cannot always be shown satisfactorily. One further limitation is that the small bowel cannot be scanned continuously.

### Gastrointestinal wall layers

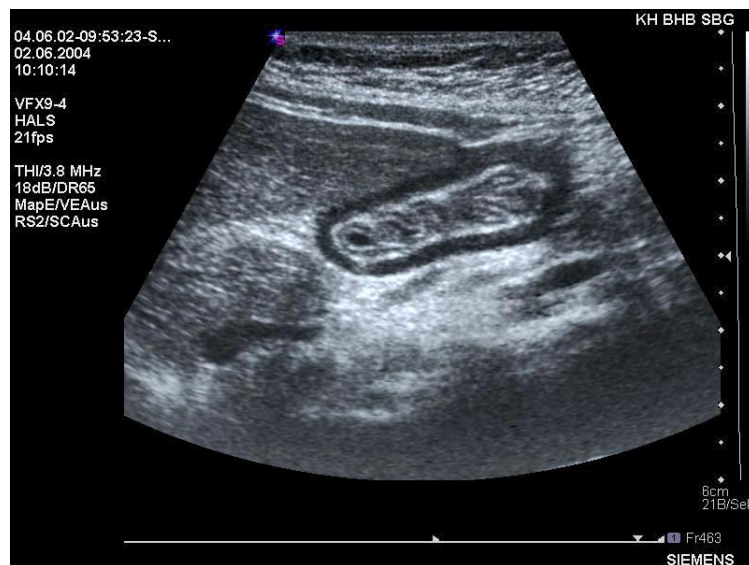High-resolution transducers usually permit visualisation of five concentric layers of the normal gastrointestinal wall [Figure 5]:

- outer hyperechoic layer – serosa and interface to the serosa
- outer hypoechoic layer – muscularis propria
- middle hyperechoic layer – submucosa
- inner hypoechoic layer – mucosa
- inner hyperechoic layer – superficial mucosal interface

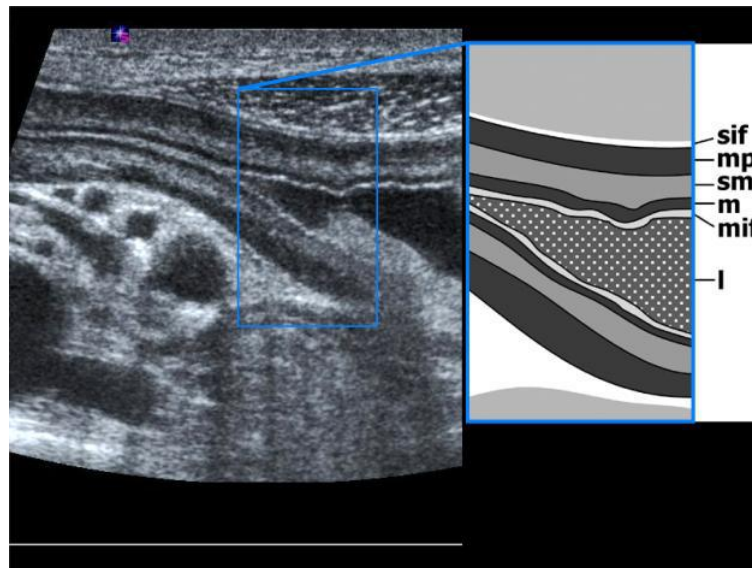
The gastrointestinal tract is supplied by three main visceral arteries: the celiac trunk; the superior mesenteric artery; the inferior mesenteric artery. Arteries, veins, nerves, and lymphatics run in the mesentery to and from the bowel segments.

**Figure 5 Gastric wall layers. Cross section (a) and zoomed longitudinal section (b) of the gastric antrum show the different wall layers. (sif: serosal interface; mp: muscularis propria; sm: submucosa; m: mucosa; mif: mucosal interface; l: lumen).**

a



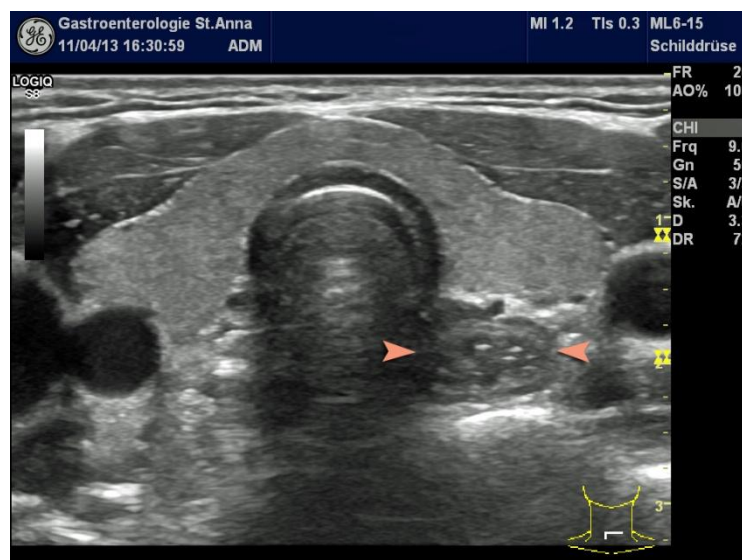
b



## Oesophagus

Transcutaneous examination of the oesophagus is used only in rare cases, e.g. obstruction with the inability to carry out endoscopy. The cervical part of oesophagus could easily be found in a transverse section behind the left thyroid lobe [Figure 6]. Rotating 90° clockwise you get to a longitudinal section and can detect small air bubbles when the patient is asked to swallow.

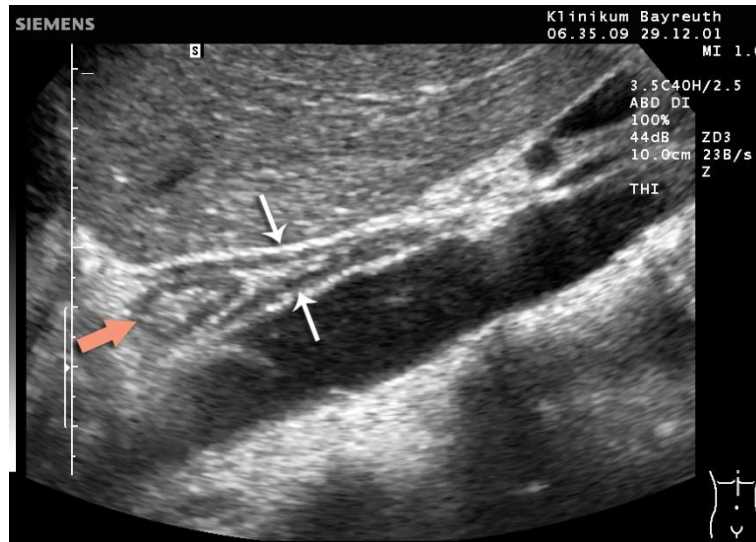
**Figure 6 Cross section in the thyroid area. Behind the left thyroid lobe the cervical oesophagus can be found.**



Intrathoracic oesophagus normally is not accessible by transcutaneous probes. Only the most distal 3-5 centimetres can be investigated via a subxiphoidal approach between left liver lobe and aorta [Figure 7]. Left side position of the patient may improve examination conditions.



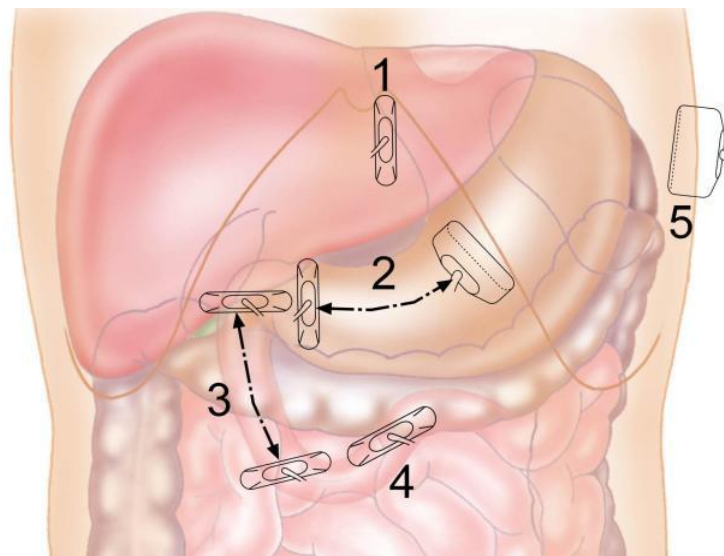
**Figure 7** Distal oesophagus / cardia (wide red arrow) between left liver lobe and aorta. It is encased by the crura of the diaphragm (narrow white arrows).



### Stomach, Duodenum

The stomach is scanned in longitudinal and transverse sections via a subxiphoidal approach from the cardia to the pylorus [Figure 8]. The fundus can be demonstrated in a translienal view. The duodenum is identified by its “C-shaped” course around the pancreatic head and the location of the third part of the duodenum between the aorta and the superior mesenteric vessels.

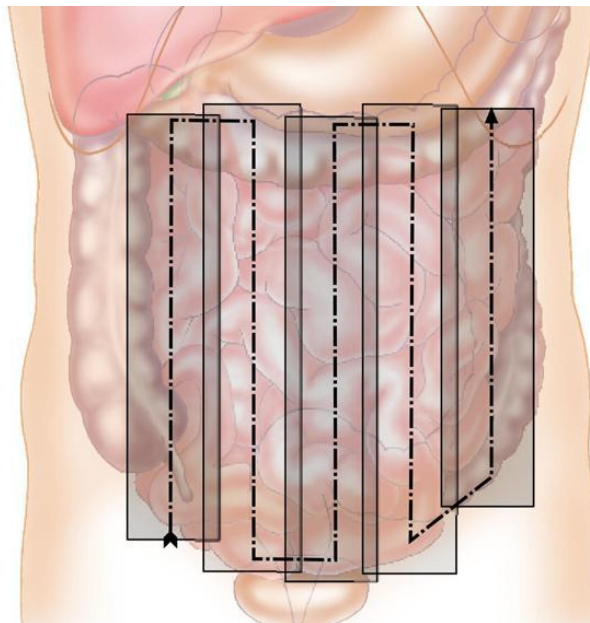
**Figure 8** Examination technique of the upper gastrointestinal tract. The stomach and the duodenum are scanned by standardized longitudinal and transverse sections through the upper abdomen.



## Small bowel

The small bowel cannot be evaluated continuously. Systemic examination is performed by making vertical, parallel, and overlapping lanes with the transducer [Figure 9]. The jejunum usually is located in the left upper and mid abdomen and the ileum in the right mid and lower abdomen. The right iliac vessels are a landmark of the ileocecal region. Fluid-filled small bowel loops allow optimal visualisation of the circular folds (valves of Kerckring or valvulae conniventes).

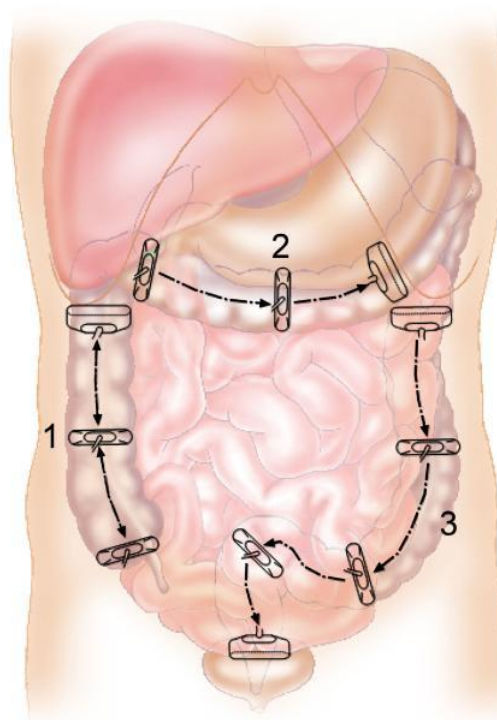
**Figure 9 Examination technique of the small bowel. The small bowel is scanned systematically by parallel overlapping lanes (like “mowing the lawn”). The terminal ileum can be demonstrated on its course over the psoas muscle and the iliac vessels.**



## Colon

Systemic examination of the colon is performed in transverse sections to each segment [Figure 10]. Typically colon ascendens and colon descendens are most lateral segments of intestine in the abdomen. First, the ascending colon is identified in the right upper quadrant and followed to the cecum. Then the colon is followed from the right colonic flexure along the transverse colon to the splenic flexure. The descending colon is identified by its laterodorsal position and scanned caudally to the sigmoid colon which takes a variable course over the left iliac vessels to the small pelvis. The rectum is visualized through the filled bladder.

**Figure 10 Examination technique of the large bowel. Systematic examination is usually performed in cross sections of the colonic segments.**



## Normal findings and its variants

In general imaging the normal GI tract is much more difficult than detecting pathological findings! That makes training of GI sonography difficult for the beginner. Acute diverticulitis emphasizes itself by surrounding hyperechoic fat and localized pain. On the other hand it may be difficult to identify a non-inflamed diverticulum or the normal appendix.

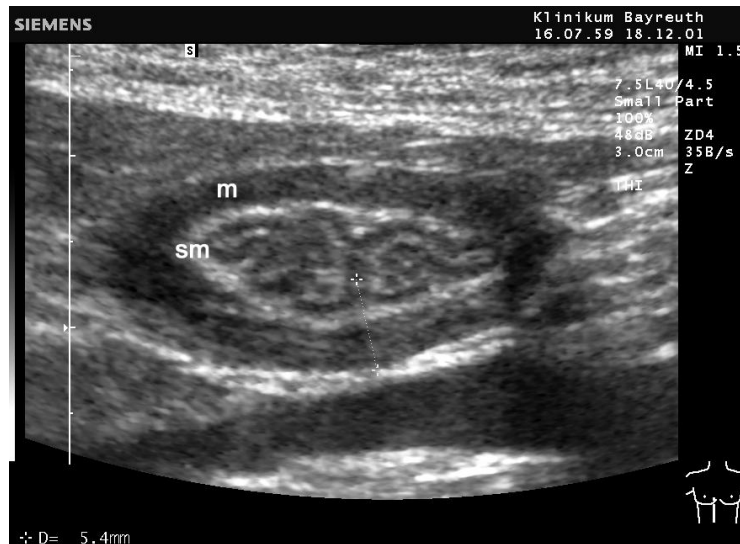
The different parts of the gut can be identified by their topographical position and certain morphological criteria. Wall thickness of the alimentary tract differs from part to part and largely depends on the state of distension or contraction. Thickness of the stomach ranges under normal conditions from 3-7 mm, of that of the small bowel and of the colon from 1-3 mm. A contracted intestinal segment must not be misinterpreted as a thickened wall.

### Stomach

The stomach easily could be found in a longitudinal section in the epigastrium: Between left liver lobe and aorta you can visualize distal oesophagus and cardia. Moving your transducer slowly to the right side (of the patient) you get a cross-section through the prepyloric antrum [Figure 11]. The rest of the stomach is quite variable: It depends to a large extent from the degree of filling and the patient's position. Postprandial food residues and entrapped gas make it impossible to

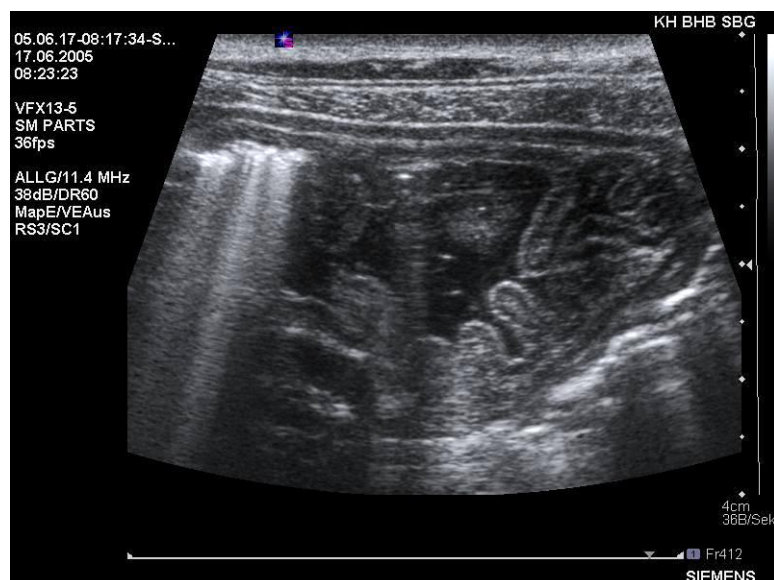
visualize the dorsal parts of the stomach. Focused examinations therefore should be carried out after an overnight fasting period.

**Figure 11 Empty stomach with linear array, crosssection in distal corpus / antrum: Thick hypoechoic lamina muscularis (m), hyperechoic lamina submucosa (sm) and gastric folds in the centre.**



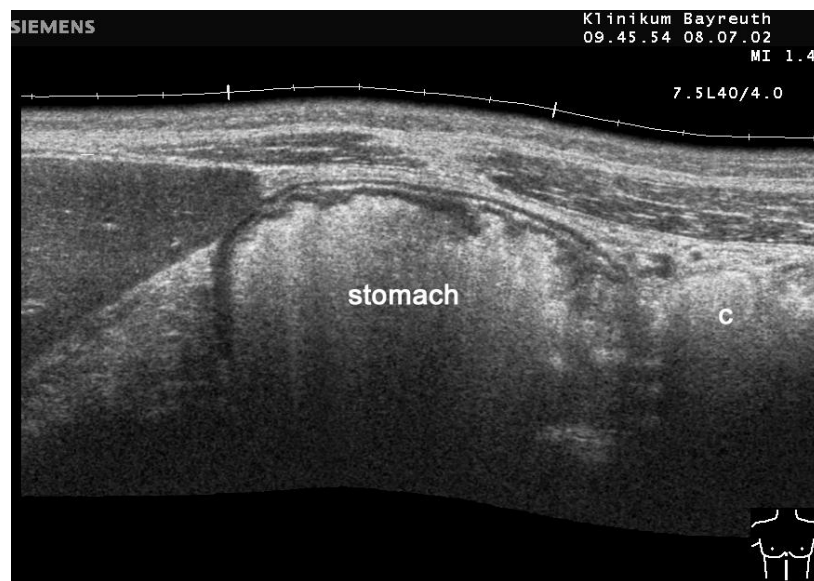Similar to other intestinal segments thickness of the gastric wall depends highly from the grade of filling. Increasing filling seems to make the wall thinner and thinner. That is the problem of standard values in the whole GI tract! Overall the muscular layer of the stomach, especially that of the antrum, is more pronounced than in other parts of the intestine [Figure 12]. Maximum thickness of the wall measures between 3 - 7 mm.

**Figure 12 Stomach with a little fluid and some gas inside. Cross section of the gastric corpus with mucosal folds protruding to the lumen.**



In an empty condition and slim patients gastric folds of the corpus may lie above one another and imitate pathological wall thickening. In this case as well as in every suspicion of general or localized wall thickening in a second step the stomach is filled with 500 ml of sparkling fluid to get a better distension (technique of fluid filled stomach).

**Figure 13 Stomach immediately after taking a meal. The corpus is filled with ingesta and gas and only the ventral stomach wall could be analysed. Caudal of the stomach appears a cross section of colon transversum (c).**



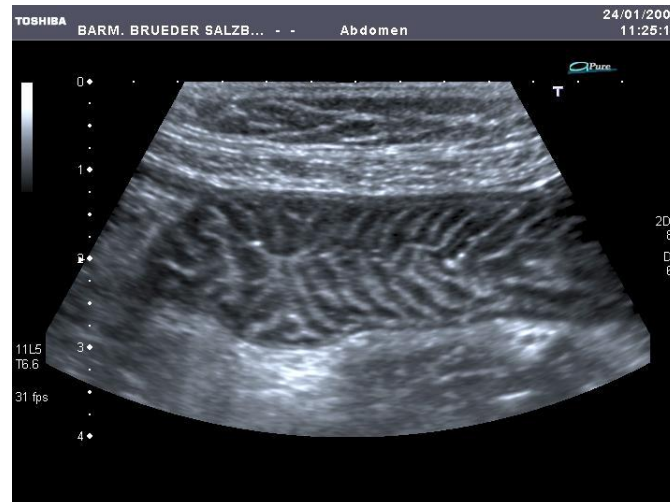
### Duodenum, small bowel

The duodenum is identified by its “C-shaped” course around the pancreatic head. In fasting patients the lumen is mostly collapsed and the thin wall is hard to distinguish from the surroundings.

The whole extent of small bowel could be evaluated only partially. Circular folds (valves of Kerckring or valvulae conniventes) are typical for the small intestine. They decrease in number and height from the proximal jejunum to the distal ileum. They are best visible when bowel loops are fluid filled [Figure 15].



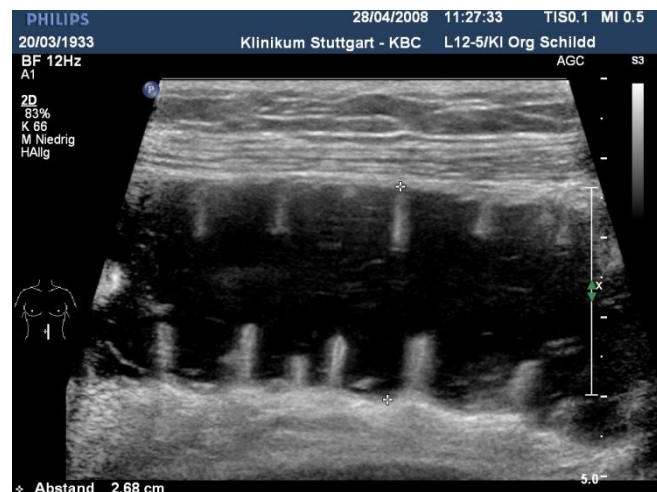**Figure 14 Small bowel. Longitudinal section of a jejunal segment showing the numerous valves of Kerckring (valvulae conniventes).**



In empty or little filled jejunal loops the valves of Kerckring sometimes lie above one another and form a fishbone pattern [Figure 14, Video 1]. That's quite normal especially in young people.

In contrast to the colon small bowel shows plenty of peristalsis but only little gas in the lumen [Video 2]. Wall thickness varies between 1 -3 mm, mostly depending on the grade of distension as mentioned above. The overall diameter of a small bowel loop should not exceed 25 mm. Dilatation to more than 25-30 mm suggests ileus or a downstream obstruction.

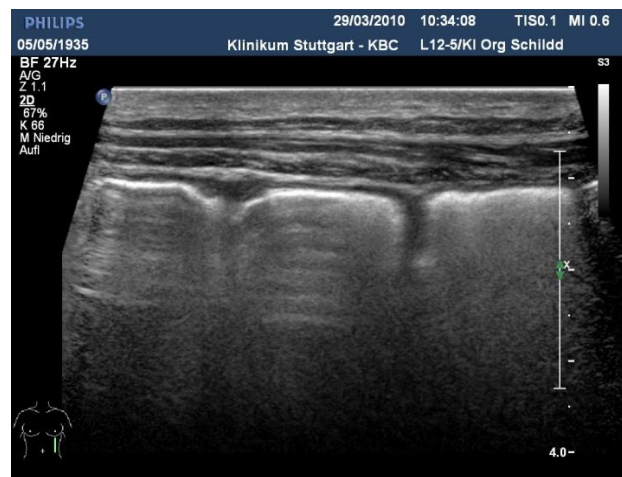**Figure 15 Proximal small bowel loop in an early state of bowel obstruction. The lumen is filled with fluid and the valves of Kerckring are clearly marked. Beginning distension of the lumen (25 mm).**



## Colon

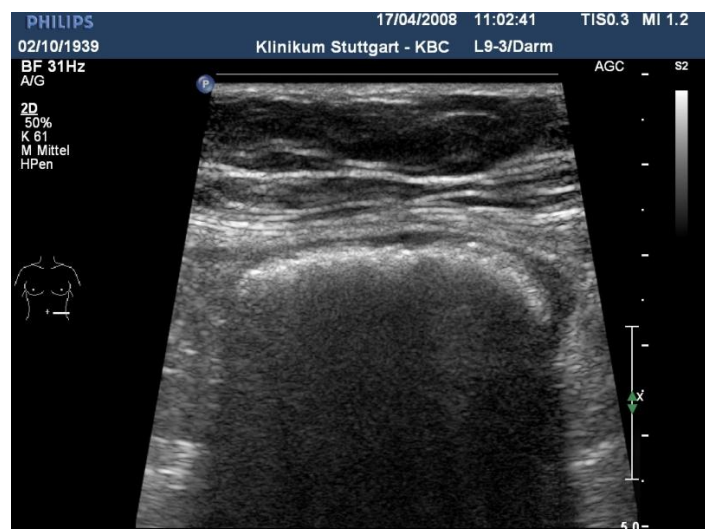The colon is characterised by its haustration which is best visible on US at the ascending and transverse colon [Figure 16]. Peristaltic waves are rare and normally much more gas is found in lumen. Intraluminal gas in many cases hinders us from imaging the distant wall of the colon and sometimes even from examining other abdominal organs.

**Figure 16 Colon. Longitudinal scan of the descending colon with its typical haustration. There is much gas in the lumen and only very rare peristalsis.**



Wall thickness varies between 1 -3 mm with maximum in the sigmoid colon. The overall diameter of colon loops extends up to 5 cm [Figure 17]. In constipated persons it may even be more.

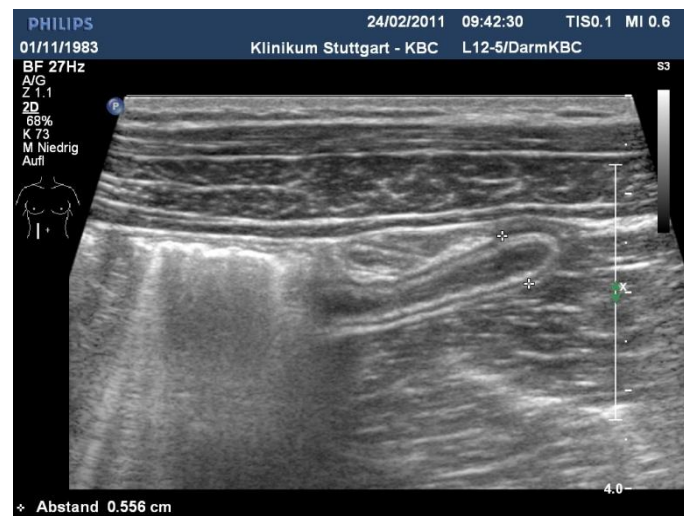**Figure 17 Colon descendens in a cross section. The diameter of 3-5 cm is larger than in small bowel loops.**



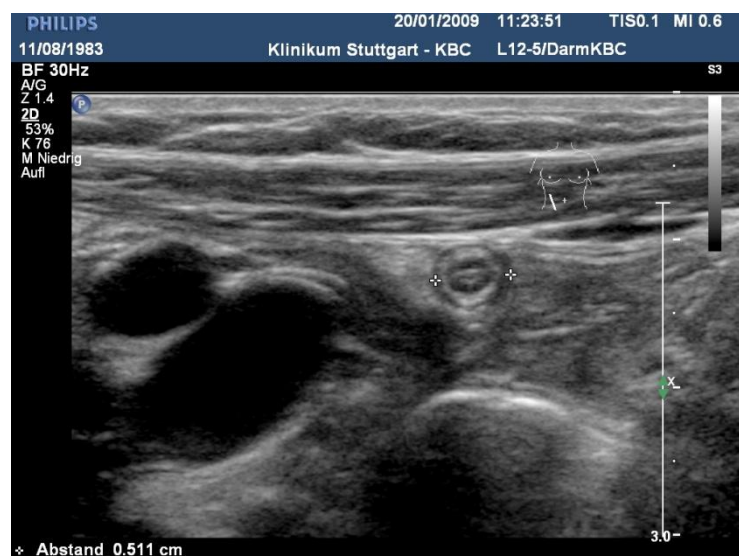## Appendix

The appendix is a blind-ending, tubular structure that arises from the cecum [Figure 18]. Normal appendix has a large variability in length and localisation. Appendix almost never shows peristaltic movement. That's a helpful criterion to distinguish it from the nearby terminal ileum. The overall transverse diameter is up to 6 mm [Figure 19, Video 3].

**Figure 18 Normal appendix.** On the left side of the picture you see the cecum with a lot of gas inside. From the cecum appendix is arising as a small blind ending tube without peristaltic movement.



**Figure 19 Normal appendix.** Cross section of appendix just after crossing the iliacal vessels (left side of the picture). The maximum transverse diameter is up to 6 mm, mostly it is a slightly ovoid and easily compressible.



## Lymph nodes

Improvement of sonographic technology enables us to identify not only enlarged, but also normal sized lymph nodes along bowel in the mesentery. Especially in the right lower abdomen and in young people some long shaped lymph nodes are quite common.

## Additional evaluation criteria

Beside thickness of the bowel wall and transverse diameter, a whole range of additional sonographic criteria is taken into consideration to make a pathological diagnosis: Stratification, echogenicity, length of the affected segment, vascularisation, associated findings in adjacent tissue et cetera. Bowel peristaltis deserves special attention which can be observed in real time by ultrasound. Detailed illustration of these pathological criteria will be given in the advanced course (see EFSUMB Course Book on Ultrasound).

## VIP: Very Important (and most frequent) Pathologies

This chapter gives you a first overview of the most frequent GI pathologies and their diagnosis by ultrasound:

1. Acute appendicitis
2. Diverticulitis
3. Bowel obstruction
4. Chronic inflammatory bowel disease (CIBD)
5. Gastrointestinal tumours

## Acute Appendicitis

Acute appendicitis is the most common cause of acute surgery in western countries. It is a common clinical problem because only 50-60% of patients present with typical clinical symptoms. Children and adolescents are most often involved. Without the use of imaging methods the incidence of negative laparotomies may be up to 45% especially in women of child-bearing age.

The appendix is a blind-ending, tubular structure that arises from the cecum. The normal appendix shows three wall layers similar to the rest of the intestine. It frequently courses from the iliac fossa medial and caudal over the iliopsoas muscle, is oval shaped under compression, and contains some gas or fecal material. But the position of the appendix varies in that it courses in different directions or even retrocecal.

Appendicitis often is triggered by luminal obstruction due to infectious swelling of the wall, fecaliths, lymphatic hyperplasia or food remnants.

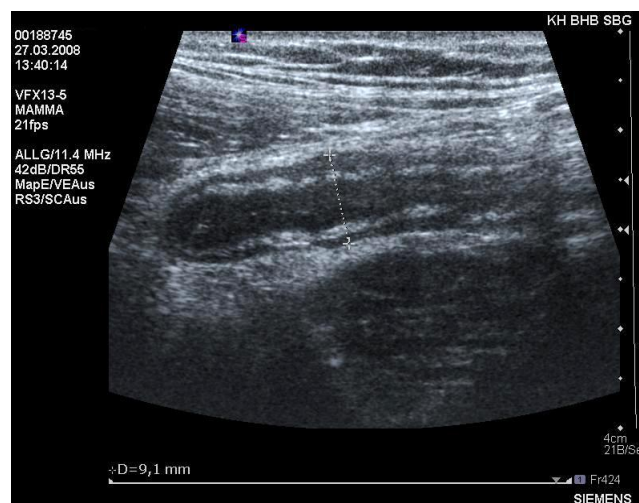
The most important sonographic criteria of acute appendicitis are:

- **A noncompressible appendix with a diameter >6 mm:** Either the wall is thickened by the acute inflammation or the lumen is distended and filled with purulent content; initially the wall layers are preserved but the more the inflammation extends, the more the layers are destroyed.
- **Point of maximum tenderness** over the appendix.

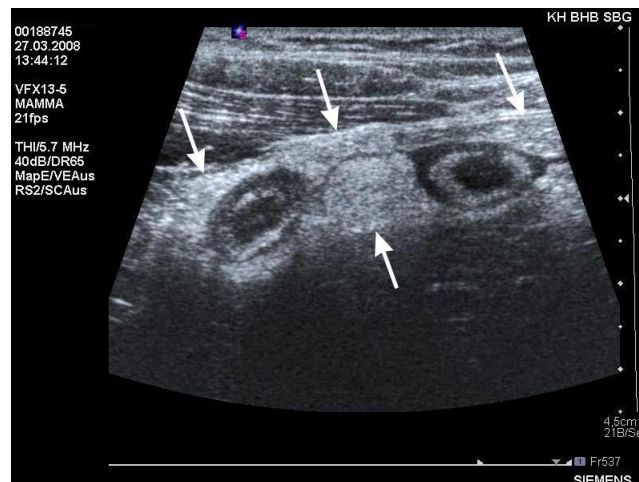
- **Hyperechoic changes of the surrounding fatty tissue** and loss of compressibility; in more severe cases hypoechoic changes and fibrinopurulent exsudate may be visible; adjacent bowel loops such as the cecum and terminal ileum are often involved and thickened [Figure 20, 21, Video 4].

**Figure 20 a,b Appendicitis. Longitudinal view of the thickened appendix (a). The wall layers are visible but the hyperechoic submucosa is partly disrupted in this case of phlegmonous appendicitis. On the transverse view (b) the appendix is visible twice due to its winding course. This scan also demonstrates the inflammatory changes of the periappendiceal mesenteric and omental fat better (arrows).**

a

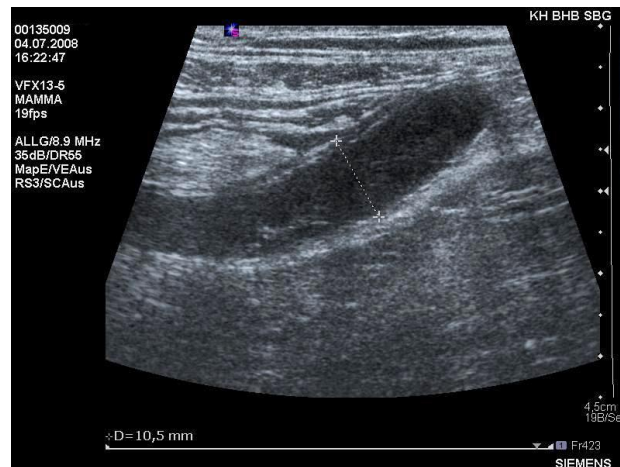


b



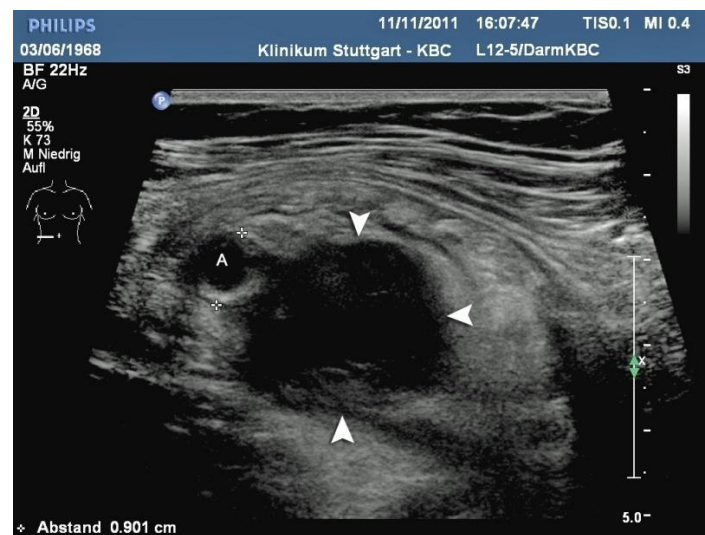

**Figure 21 Appendicitis.** In this case no significant wall thickening is present but the lumen is distended and filled with purulent content.

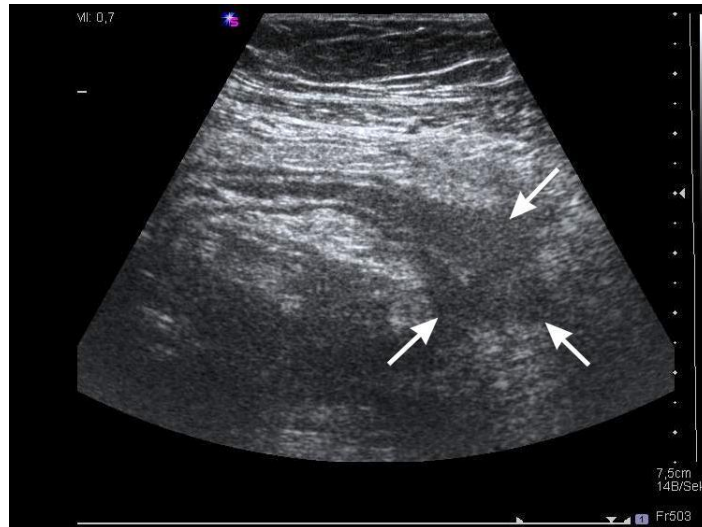


In the case of a perforated appendix the appendiceal wall is at least partly destroyed and signs of local peritonitis are present. If a perityphlitic abscess forms, a retention of mixed echogenicity with or without gas bubbles can be demonstrated [Figure 22, 23, Video 5]. Free intraperitoneal gas is only rarely seen.

**Figure 22 Perityphlitic abscess (arrows).** A hypoechoic fluid collection is visible in the right lower quadrant just beside the enlarged appendix (A). The wall of the appendix is partially destroyed.



**Figure 23 Perforated appendix.** The proximal part of the appendix is well delineated whereas the distal part is destroyed (arrows) in this case of a perforation at the tip of the appendix.



Most common causes of false-negative sonographic results are: only the tip of the appendix is inflamed; atypical appendiceal position (small pelvis, retrocecal); a gangrenous gas-filled appendix; a perforated, non identifiable appendix.

Especially in adipose patients CT is the next step if US cannot identify the appendix and suspicion of appendicitis is high. MRI is an alternative method in young patients and pregnant women.

The most important differential diagnoses of acute appendicitis include inflammatory diseases of the bowel, various gynaecological and urological diseases, perforated cecal carcinoma, omental infarction as well as a number of rare findings. Some acute conditions of the abdominal wall and of the retroperitoneum such as an incarcerated hernia or a hematoma of the psoas muscle may also mimic appendicitis.

## Diverticulitis

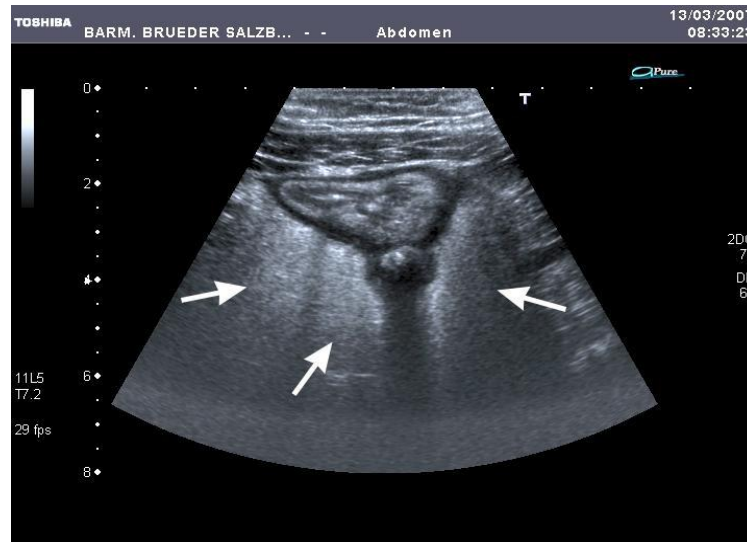Diverticulitis is a frequent cause of left lower quadrant pain and its incidence is still rising. Almost all clinically significant cases of diverticulitis are a result of microperforation of the thin-walled pseudodiverticula which are predominantly located in the sigmoid colon.

US and CT are the imaging methods of choice because inflammation primarily involves the pericolic structures, especially the fatty tissue of the mesocolon and of epiploic appendages.

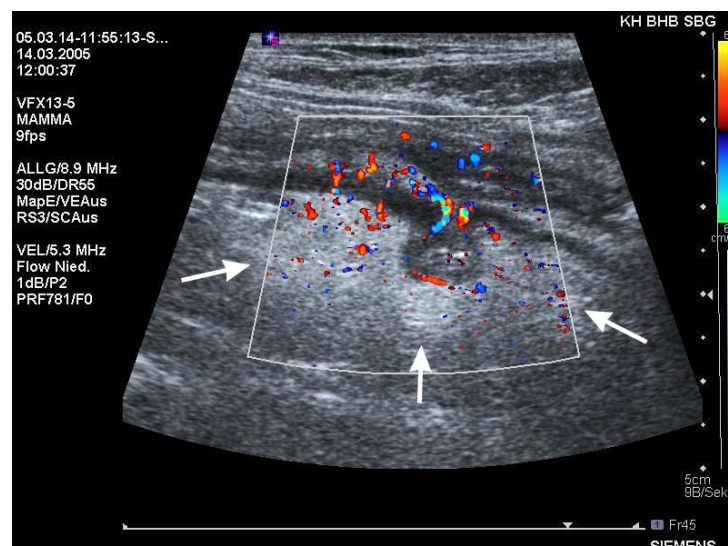
The presence of the three following criteria allows a specific sonographic diagnosis of diverticulitis:

- **Short segmental bowel-wall thickening:** the bowel wall layers may be preserved.
- **Alteration of the pericolic fat** ranging from hyperechoic noncompressible fat to hypoechoic phlegmonous inflammation with fibrinopurulent exsudate.
- **Demonstration of the inflamed diverticulum and localized pain in this area:** in contrast to normal diverticula they are hypoechoic or hyperechoic with a hypoechoic rim and are surrounded by hyperechoic fatty tissue [Figure 24, 25, Video 6].

**Figure 24 Sigmoid diverticulitis.** This transverse scan of the sigmoid colon shows all typical criteria of diverticulitis. The wall layers of the thickened colonic wall are preserved. The inflamed diverticulum contains a fecalith and is surrounded by a hypoechoic rim and hyperechoic fatty tissue (arrows).



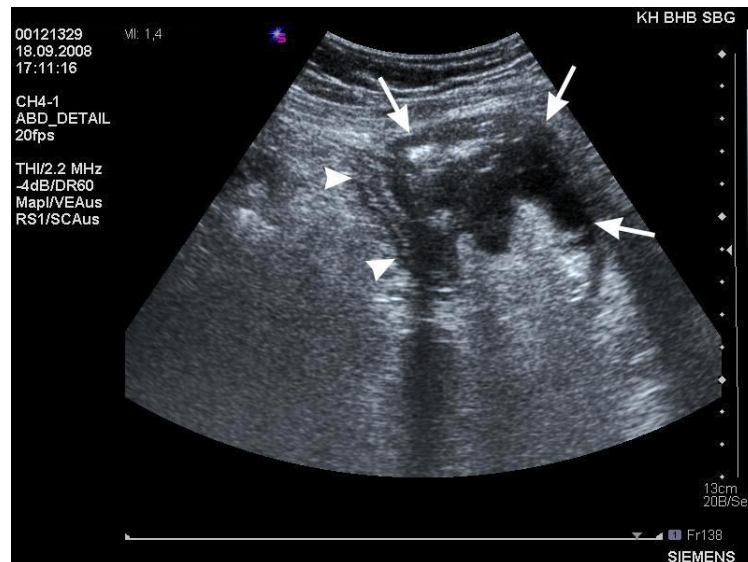
**Figure 25 Sigmoid diverticulitis.** Colour Doppler image demonstrates hypervascularity in the colonic wall, in the wall of the diverticulum, and in the inflamed peridiverticular fat (arrows).



The lower sigmoid colon may be difficult to assess by transabdominal ultrasound. In this case a short-term follow-up with filled bladder might give you a better insight. The typical complications of diverticulitis include abscess formation, fistulas, perforation and stenosis [Figure 26]. Hypoechoic abscesses are usually well detectable with US whereas predominantly hyperechoic, gas-containing abscesses

are sometimes difficult to differentiate from bowel loops. If this is the case and if clinical signs and sonographic results are discrepant, CT should be performed.

**Figure 26 Peridiverticular abscess.** This complex gas-containing lesion (arrows) adjacent to the sigmoid colon (arrowheads) represents a peridiverticular abscess.



Fistulas may present as hypoechoic bands with central gas bubbles. Gas in the urinary bladder is an indirect sign of a sigmoid-vesical fistula.

### **Bowel obstruction**

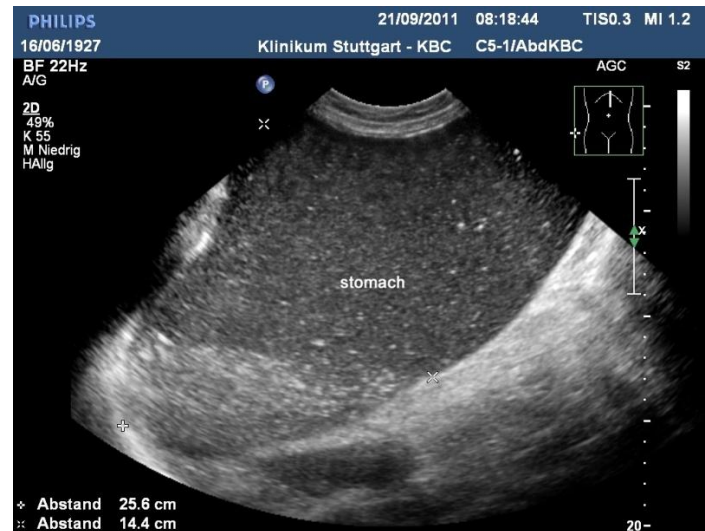Patients with clinical signs of bowel obstruction such as abdominal pain, abdominal distension, and vomiting need immediate diagnostic evaluation. Nowadays plain radiographs are for the most part replaced by US and CT. These methods allow earlier proof of bowel obstruction, the cause of obstruction can often be demonstrated and alternative diagnoses can be established.

The level of obstruction can be determined by careful analysis of dilated bowel segments. The duodenum can be recognized next to the pancreatic head and the third part passes to the left side posterior to the superior mesenteric vessels. The dilated jejunum can be distinguished from the ileum by the pattern of the valvulae conniventes and to some degree by the location in the abdomen. The colon is characterized by its typical haustra. Moreover, the ascending and the descending colon are fixed to the retroperitoneum laterodorsally in the abdominal cavity.

### **Gastric outlet and duodenal obstruction**

Chronic duodenal ulcer and tumours of the stomach or the pancreatic head are the most common causes of upper gastrointestinal obstruction [Figure 27]. Plain radiographs are frequently false negative in these cases because vomiting results in lack of air in the obstructed segment. US easily detects the dilated stomach with ingested food and fluid-fluid levels. The dilated duodenum or the dilated segment in an afferent-loop syndrome is also reliably demonstrable.

**Figure 27 Upper gastrointestinal obstruction. US image shows dilatation of the stomach (25 cm!) with a fluid-fluid level and sedimentation. Patient needs a gastric tube urgently to prevent aspiration.**



### **Small bowel obstruction**

About two thirds of small bowel obstructions are caused by adhesions. In this situation usually no abnormality is visible at the point of transition from dilated bowel to normal bowel. Other reasons of small bowel obstruction such as tumours, hernias, Crohn's disease, bezoars, or a perforated gallstone can be demonstrated by US [Figure 29].

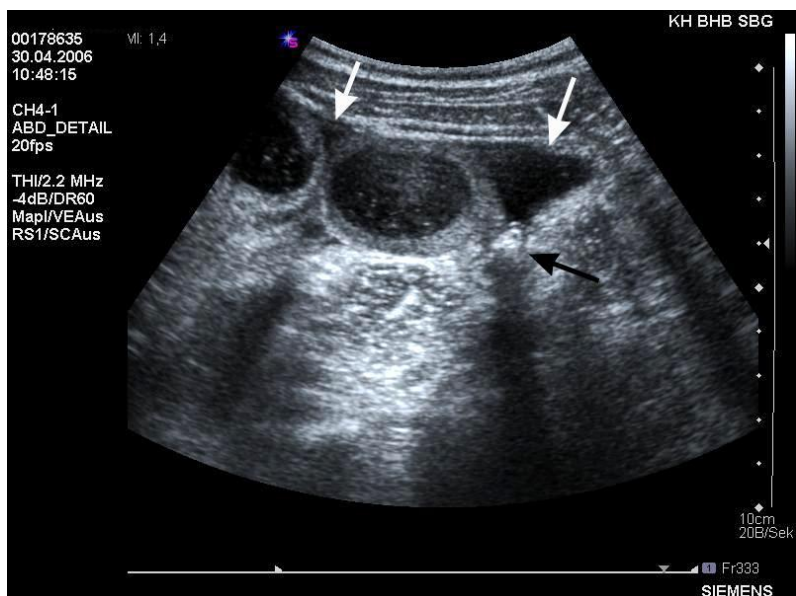
Small bowel obstruction must be considered to be present when:

- the lumen of the fluid-filled small bowel loops is  $\geq 3$  cm [Video 7];
- peristalsis of the dilated segment is increased;
- bowel loops distal to the stenosis are collapsed [Figure 28].

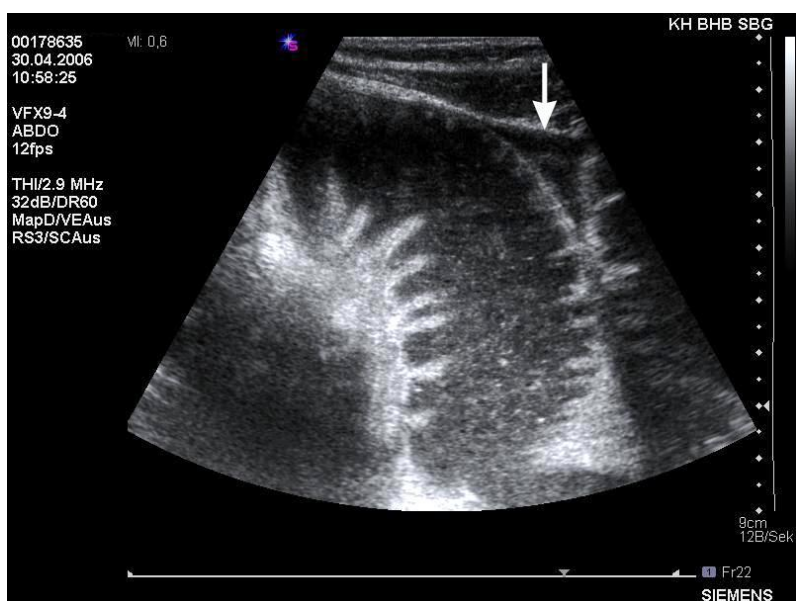
**Figure 28 Small bowel obstruction. Cross section (a) in the left mid abdomen shows dilated fluid filled small-bowel loops and the contracted descending colon (black arrow). Free fluid in the peritoneal cavity (white arrows) is also present. The numerous valvulae conniventes protruding to the dilated lumen are characteristic for the jejunum (b).**

a

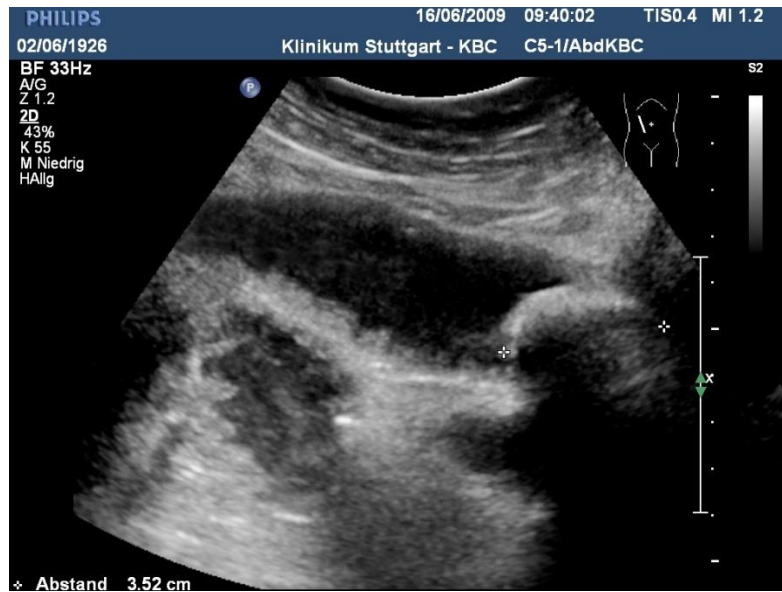



b



**Figure 29 Gallstone ileus. Obstruction in this case was caused by a large gallstone visible in the lumen of the small bowel.**



A small amount of intraperitoneal fluid is frequently present. Difficulties may arise when the obstruction becomes prolonged and the dilated segment becomes paralytic. This situation should not be mistaken for paralytic ileus. Contracted bowel loops distal to the stenosis still allow correct diagnosis.

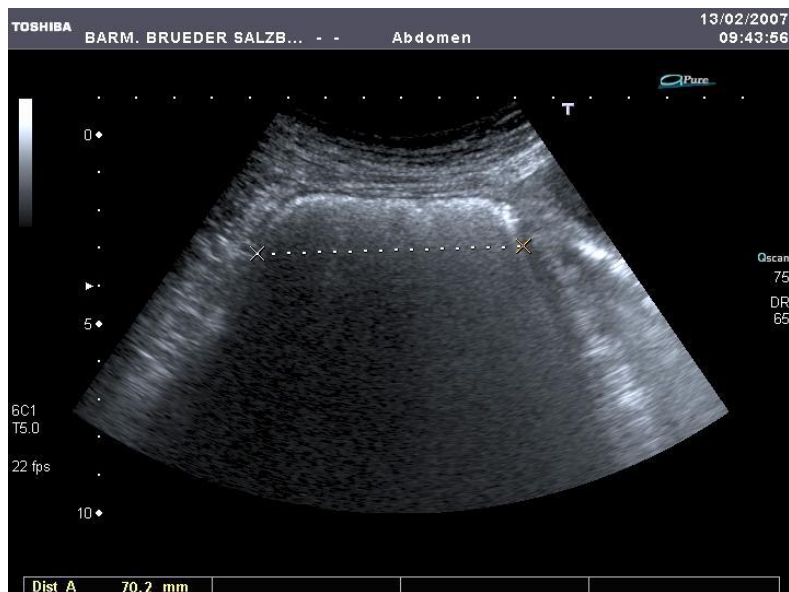
An akinetic dilated bowel loop, thickening of the bowel wall and the leaves of the mesentery, and increased intraperitoneal fluid are suspect of strangulation which requires immediate surgery. Closed-loop obstruction with a typical “omega shaped” distended loop or a conglomerate of fluid-filled loops is such a situation in which strangulation frequently occurs.

### **Large bowel obstruction**

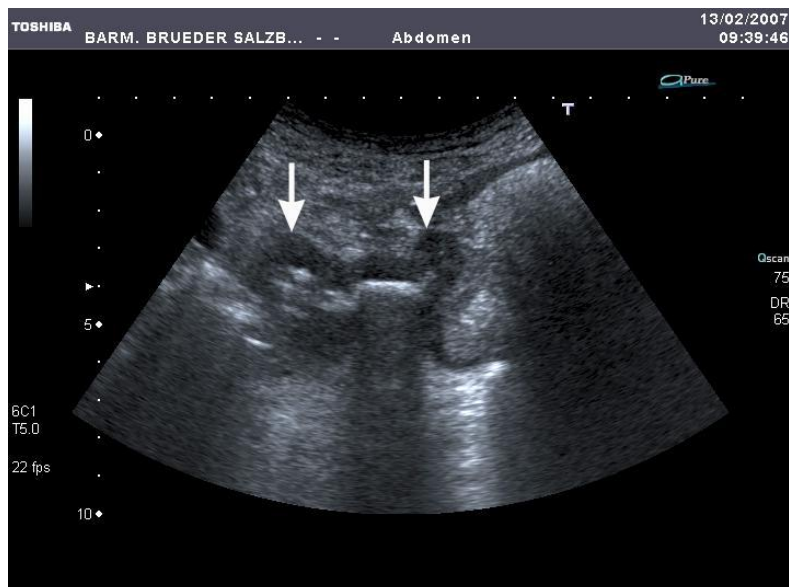
Tumours of the colon are the most common cause of large bowel obstruction. Other causes include volvulus, inflammation, and scar shrinkage due to inflammation or ischemia. US shows the dilated colon with usually hyperechoic content [Figure 30]. Due to disturbing gas it is sometimes difficult to get a clear overview and to determine the site of stenosis. In this situation CT is the next method to establish the correct diagnosis.

**Figure 30 Large bowel obstruction. The descending colon is dilated and filled with feces and gas (a). Massive dilatation and obscuring gas may hinder adequate evaluation of the underlying cause. A carcinoma of the sigmoid colon (arrows) with a stenotic irregular lumen was the cause of the obstruction in this patient (b).**

a

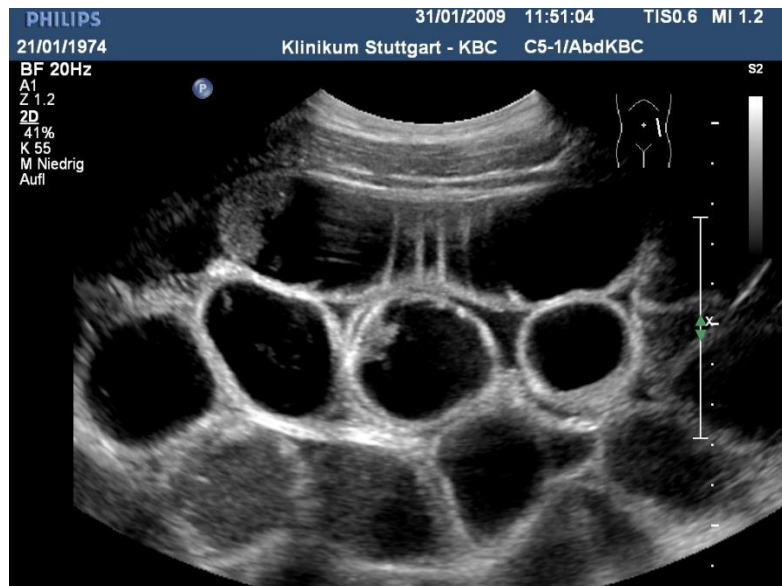

b



Bowel obstruction must be differentiated from paralytic ileus and other conditions leading to dilatation of the lumen. In paralytic ileus usually both the small bowel and the large bowel are dilated and peristalsis is reduced [Figure 31]. Delayed gastric emptying may also be caused by inadequate peristalsis due to a number of diseases.

**Figure 31 Paralytic ileus. Numerous fluid filled, dilated, and aperistaltic small bowel loops are visible in this patient four days after cesarean section. The large bowel (not shown) was also dilated and partly fluid filled.**



### Chronic inflammatory bowel disease (CIBD)

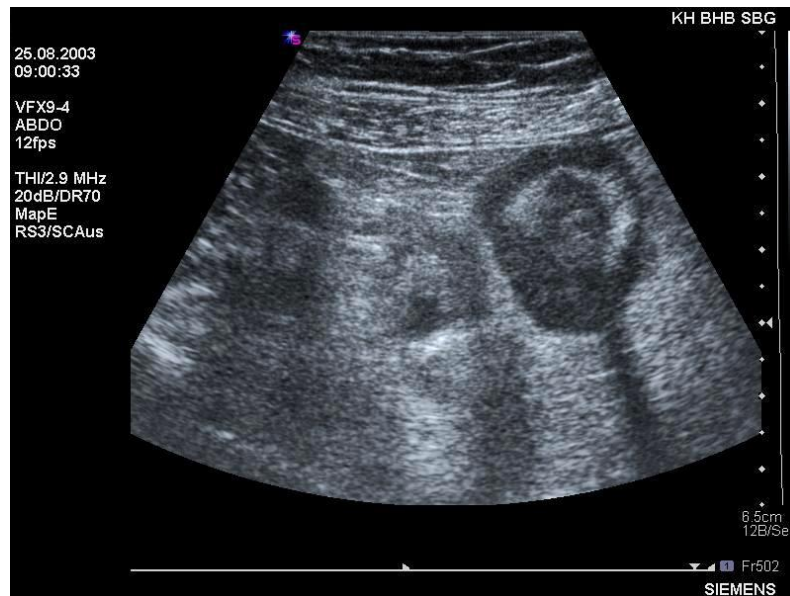Both Crohn's disease and ulcerative colitis typically occur in young adults but may also affect children or elderly patients. Clinical signs such as cramping abdominal pain, diarrhoea, and rectal bleeding sometimes precede the definite diagnosis for months. US signs of chronic inflammatory bowel disease especially in Crohn's disease contribute to earlier endoscopic and histological proof. B-mode US, Colour Doppler imaging and more recently contrast enhanced US may give additional information on activity of disease and success of treatment.

#### *Crohn's disease*

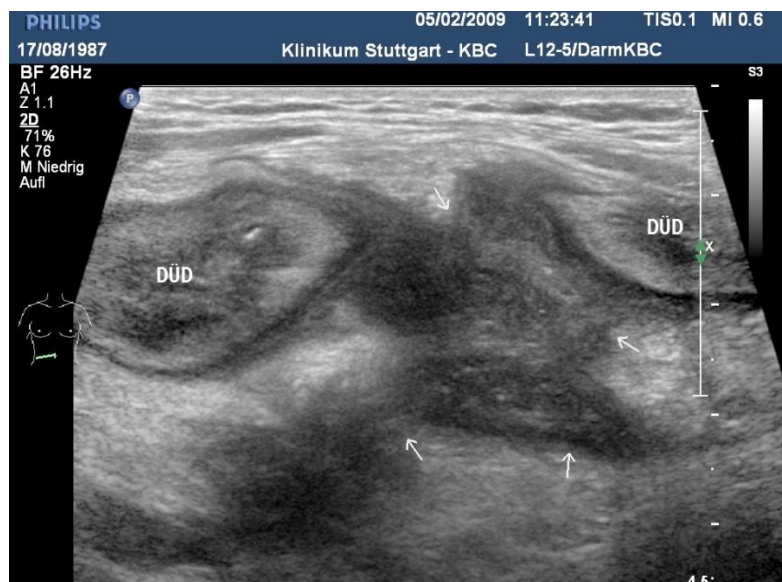Crohn's disease predominantly involves the distal ileum and the colon. The affected bowel segment appears markedly thickened and the lumen is narrowed resulting in the classic sonographic "target sign" on transverse images. In contrast to ulcerative colitis, involvement is discontinuous with intervals of normal bowel producing "skip areas". Transmural inflammation through all layers of the intestinal wall is another typical sign of the disease and can lead to complete loss of stratification. The mesentery and other adjacent structures are frequently involved in the inflammatory process. The affected bowel is then surrounded by noncompressible fatty tissue which is sometimes traversed by finger like hypoechoic bands. The evidence of hypertrophic fat around the bowel is also called the "creeping fat sign". Enlargement of mesenteric lymph nodes is frequently present, usually in the right lower quadrant [Figure 32, 33, Video 8].

**Figure 32 Crohn's disease. A cross section in the right lower quadrant shows the thickened terminal ileum. Stratification is partly preserved and**

**partly destroyed. The inflamed bowel loop is surrounded by hyperechoic mesenteric fat.**



**Figure 33 Crohn's disease. Severe inflammation of the mesentery is visible as a hypoechoic irregular mass between thickened ileal loops (DüD). On Colour Doppler US (not shown) hypervascularization was visible in the hypoechoic areas.**



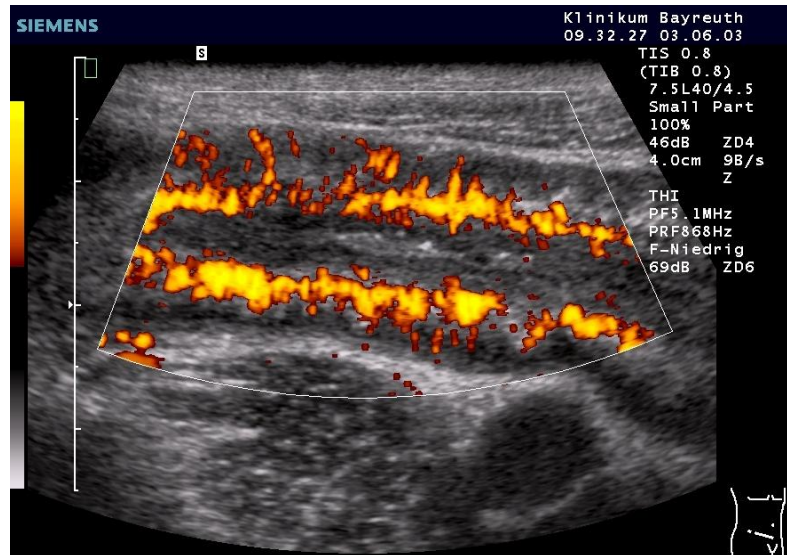
Possible complications of Crohn's disease comprise fistulas, abscess formation, bowel obstruction, and rarely, perforation. Fistulas are visible as hypoechoic tracts with hyperechoic gas inclusions. Abscesses are seen as poorly defined, mostly hypoechoic focal masses that can contain hyperechoic gas.

Many studies about pulsed Doppler and Colour Doppler imaging of disease activity have been published. Colour Doppler has also been used to facilitate differentiation of inflammatory from fibrotic stenosis in patients with obstructive Crohn's disease



[Figure 34]. However, results remain somewhat controversial because neovascularisation overlaps with increased perfusion in acute inflammation.

**Figure 34 Crohn's disease. Hypervascularization of the terminal ileum in a patient with highly active Crohn's disease.**

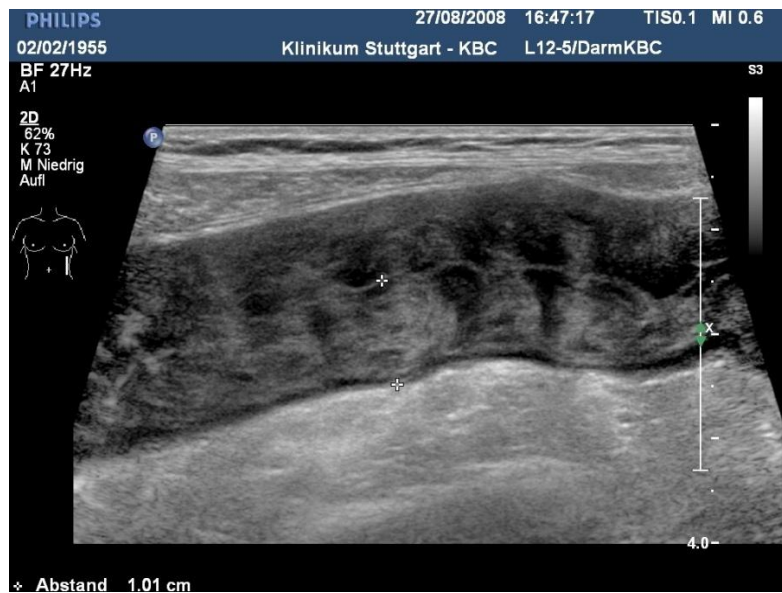

### ***Ulcerative colitis***

Colon involvement in ulcerative colitis is continuous from the rectum more or less extended to the upper colon. Bowel wall thickening is usually less marked and stratification is preserved because inflammation is predominantly located in the mucosa. In cases of acute inflammation the submucosa is thickened mainly due to oedema and tends to become more hypoechoic with the severity of disease [Figure 35]. The muscular layer and the pericolic fat are usually not involved. After resolution of the acute inflammation the colon wall returns to normal appearance or remains slightly thickened with a hyperechoic submucosa after several recurrences.

Toxic megacolon is a potentially lethal complication of ulcerative colitis in which the colon is distended and signs of toxicity are present.

**Figure 35 Ulcerative colitis.** An acute episode of ulcerative colitis led to this marked hypoechoic thickening of the colonic wall. Stratification is indefinite and hypervascularization is present (not shown).



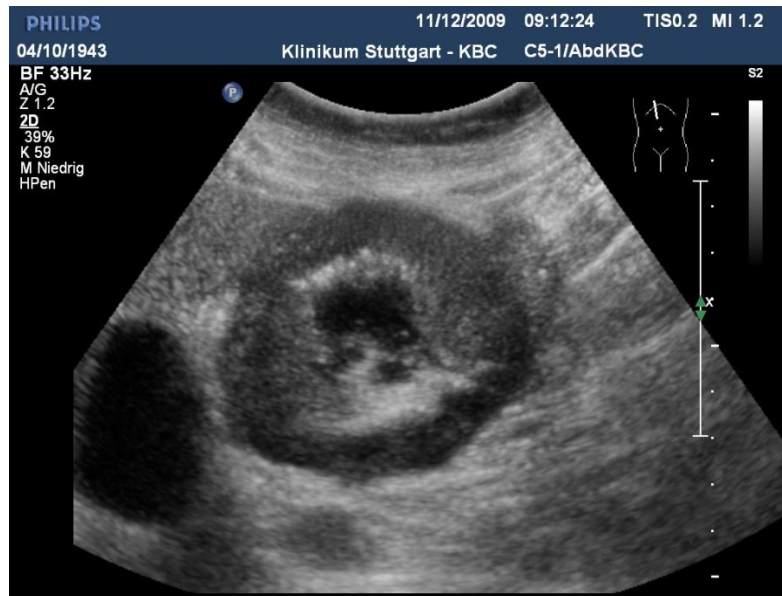### Neoplastic disease

Abdominal US is often the first imaging method that patients with gastrointestinal tumours undergo when they present with non-specific symptoms. Careful sonographic evaluation of the gastrointestinal tract may disclose focal masses. Tumours may be seen as polypoid lesions or as semicircumferential / circumferential wall thickening with wall layers frequently being destroyed. Local lymph node enlargement and focal liver lesions are signs of metastatic spread.

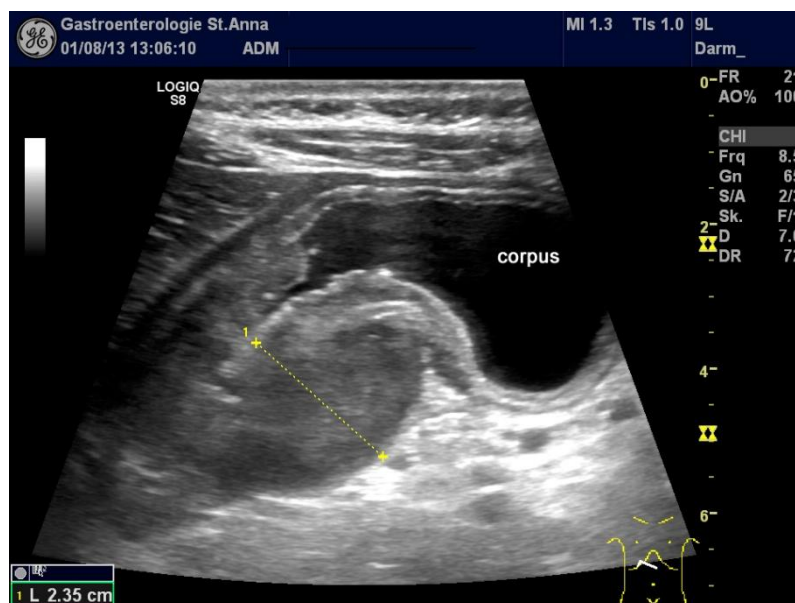
### Gastric tumours

Gastric cancer produces a localised or diffuse hypoechoic wall thickening with destruction of normal layered appearance [Figure 36, 37, Video 9]. US is not primarily used to diagnose gastric cancer but may give additional information about local tumour infiltration. It may also be helpful in cases of scirrhus-type gastric cancer if endoscopy with biopsy is negative although significant thickening of the gastric wall is visible on US examination.

**Figure 36 Gastric cancer. Circular thickening of the gastric corpus with destruction of the normal stratification by a scirrhus carcinoma (target sign).**



**Figure 37 Gastric cancer. After drinking 400 ml water you recognize normal wall layer in the corpus. The antrum (on the left side of the picture) could not distend and shows a marked wall thickening with destruction of the normal layers and stenosis.**



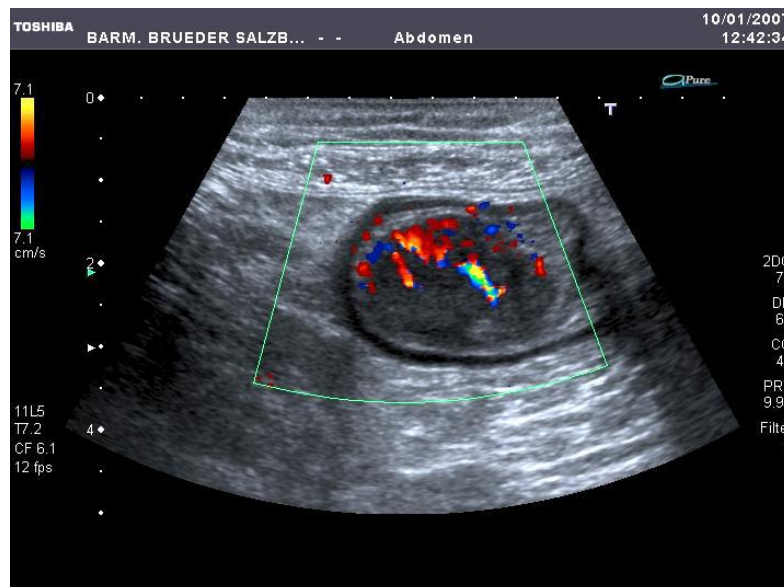
The stomach is the most common site of gastrointestinal Non-Hodgkin's Lymphoma followed by the small intestine and the colon. Circumferential, profoundly hypoechoic, and extensive wall thickening is indicative of a lymphoma. Advance stages are accompanied by enlargement of abdominal lymph nodes.

Gastrointestinal stromal tumours (GIST) are mesenchymal tumours originating from the interstitial cells of Cajal which are located in the muscular layer. 60% occur in the stomach and 30% in the small intestine. Stromal tumours show as hypoechoic, rounded, sharp bordered mass within the gastric wall. The technique of fluid filled stomach may be helpful in further evaluation.

### ***Tumours of the small bowel***

Small bowel tumours are relatively rare. The most common tumours are carcinoid tumours, lymphomas, adenocarcinomas, and gastrointestinal stromal tumours. Carcinoid tumours are small and mesenteric lymph node metastases are often detected earlier than the primary tumour [Figure 38]. GISTs are seen as focal hypoechoic masses protruding from the bowel wall. Intussusception may occur as a consequence of such a mass. Both tumours are hypervascularised on Colour Doppler US. Hypoechoic "pseudocystic" appearance of bowel wall thickening and of enlarged lymph nodes is indicative of an intestinal lymphoma.

**Figure 38 Neuroendocrine carcinoma of the ileum. A polypoid tumour was detected in the ileum in an asymptomatic patient. The tumour probably originates from the mucosa and is hypervascularized. Histologic examination revealed a neuroendocrine carcinoma with small lymph node metastases.**

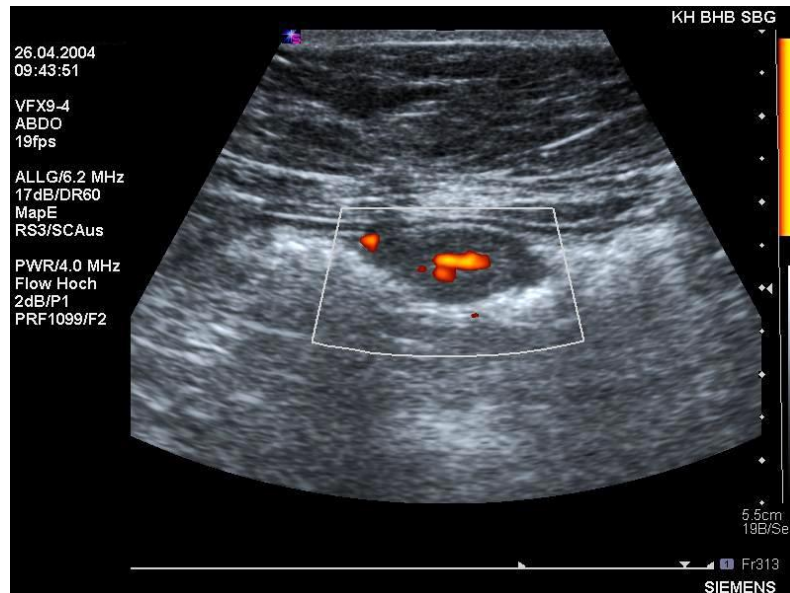


### ***Tumours of the colon***

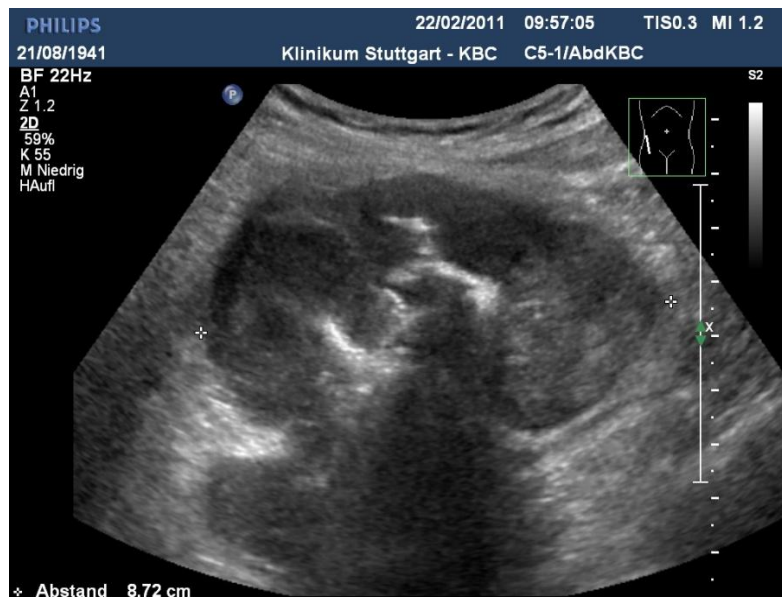Colorectal cancer is the second most common tumour in the western world. Colonoscopy and radiological methods are the screening methods for these carcinomas which usually evolve from adenomatous polyps over several years. US in experienced hands can demonstrate a high percentage of T3 and T4 tumours and about one third of T1 and T2 tumours. Polyps are only demonstrable in a minority of cases [Figure 39]. Colour Doppler US can help to differentiate polyps from hypoechoic fecal material. Carcinomas usually present as hypoechoic short

segmental and asymmetric wall thickening. Bowel wall layers are increasingly destroyed with tumour progression [Figure 40, Video 10].

**Figure 39 Colonic polyp. Power Doppler US clearly shows vascularization in the ovoid hypoechoic lesion in the transverse colon.**



**Figure 40 Colon cancer. Advanced tumour (T3) of the coecum with circular thickening of the wall. So called “pseudo-kidney sign” because at first view it looks similar.**



Loss of outer smooth delineation of the colonic wall is indicative of tumorous infiltration to the pericolic fat and adjacent organs. Patients with colonic cancer are



also evaluated for local lymph node enlargement and focal liver lesions as a sign of metastatic spread.

Other tumours of the colon include lymphomas, GIST's, and lipomas. Lipomas are hyperechoic in contrast to GIST's. GIST's and lymphomas are usually hypervascularised on Colour Doppler US.

## GI ultrasound in clinical practice

Ultrasound in Europe is the leading imaging method in patients with acute abdominal problems. It's available in the medical office of many physicians as well as in nearly every emergency room. Ultrasound examination immediately follows after physical examination and in a high percentage leads to definitive diagnosis (bedside diagnostics or recently revival as "point of care diagnostics" in the USA). Portable ultrasound machines allow examinations even in intensive care units or nursing homes.

US also is a valuable tool for monitoring chronic intestinal diseases: Here it gives additional information to endoscopic or radiological examinations and can replace radiological x-ray exposition or expensive MR imaging.

Last but not least we demonstrated GI tumours which are not so rare an incidental finding, if you always have a short look at the GI tract in routine ultrasound.

## Recommended reading

- Hollerweger A, Dirks K, Szopinski K: Transabdominal ultrasound of the gastrointestinal tract. In: Dietrich CF. EFSUMB Course Book on Ultrasound, London 2012 ([www.efsumb.org](http://www.efsumb.org)).
- EFSUMB Cases of the Month ([www.efsumb.org](http://www.efsumb.org)).
- Lutz H, Deuerling J: Gastrointestinal tract (Chapter 11). In: Lutz H, Buscarini E. Manual of diagnostic ultrasound. World Health Organization, Geneva 2011 (<http://www.who.int/iris/handle/10665/43881>).
- Dirks K, Will U, Lutz H: Magen- und Darmtumore in Seitz/ Schuler/ Rettenmaier: Sonographische Diagnose und Differentialdiagnose. Thieme Stuttgart 2007.
- Dirks K: Akut entzündliche Darmerkrankungen in Seitz/ Schuler/ Rettenmaier: Sonographische Diagnose und Differentialdiagnose. Thieme Stuttgart 2007.
- Meckler U, Hollerweger A, Dietrich CF: Sonographische Differenzialdiagnose: Krankheiten des Gastrointestinaltraktes. Deutscher Ärzte-Verlag 2004.
- Nürnberg D, Ignee A, Dietrich CF: Current Status of Ultrasound in Gastroenterology-Bowel and Upper Gastrointestinal Tract-Part 1. Z Gastroenterol 2007; 45: 629-640.
- Nürnberg D, Ignee A, Dietrich CF: Current Status of Ultrasound in Gastroenterology-Bowel and Upper Gastrointestinal Tract-Part 2. Z Gastroenterol 2008; 46: 355-366.